

## REVIEW

# Point-of-care ultrasound of optic nerve sheath diameter to detect elevated intracranial pressure: Ultrasound in the eye of the beholder?

N.S. Tjahjadi<sup>1,2</sup>, W. van de Bergh<sup>6</sup>, P.W.G. Elbers<sup>1,2,3,4</sup>, D. Gommers<sup>7</sup>, P.R. Tuinman<sup>1,2,5</sup>

<sup>1</sup>Department of Intensive Care Medicine, Amsterdam University Medical Centers - location VUmc, Amsterdam, the Netherlands

<sup>2</sup>Research VUmc Intensive Care (REVIVE), Amsterdam, the Netherlands

<sup>3</sup>Amsterdam Cardiovascular Sciences, Amsterdam, the Netherlands

<sup>4</sup>Amsterdam Infection and Immunity Institute, Amsterdam, the Netherlands

<sup>5</sup>Amsterdam Leiden IC Focused Echography (ALIFE), Amsterdam, the Netherlands

<sup>6</sup>Department of Intensive Care, University Medical Center Groningen, Groningen, the Netherlands

<sup>7</sup>Department of Intensive Care, Erasmus University Medical Center, Rotterdam, the Netherlands

## Correspondence

N.S. Tjahjadi - nictjahjadi@hotmail.com

**Keywords** - ultrasound, optic nerve sheath diameter, intracranial pressure, ONSD

## Abstract

Raised intracranial pressure (ICP) is a frequent complication in neurocritically-ill patients. Current diagnostic methods are invasive and have ample drawbacks. Ultrasound of ONSD can be an alternative modality to diagnose and monitor a raised ICP. A thorough search in PubMed/EMBASE was applied to find relevant articles. Two reviewers independently evaluated the relevant articles and extracted the data.

The optimal cut-off value of ONSD to detect a raised ICP ranged from 4.7 – 5.7 mm with corresponding sensitivity and specificity rates ranging from 70% - 100% and 31.9% - 100%, respectively.

Measurements of ultrasound ONSD showed to be less accurate in presence of fluctuations of ICP values.

Ultrasound of ONSD is an accurate, safe, sensitive and specific method to detect a raised ICP. For now, ultrasound of ONSD has its limitations and must not be used as a primary modality to diagnose an elevated ICP and further research is needed.

## Introduction

Raised intracranial pressure (ICP), defined as an ICP >20 mmHg, is a serious complication of many neurological conditions and associated with poor outcome.<sup>[1, 2]</sup> The current gold standard method to diagnose and monitor changes in ICP relies on invasive ventricular catheters or intraparenchymal probes.<sup>[3]</sup> However, these invasive devices carry the risk of haemorrhage and infection, and are often only available in specialist neurocritical care centres.<sup>[4]</sup> Computed tomography (CT) is the second-choice modality to detect signs of an increased ICP. CT imaging, however, has its own limitations, such as a poor correlation between disorders on emergency

CT scan of the brain and ICP, radiation exposure, high costs, it is time consuming and carries the risk associated with patient transport.<sup>[5]</sup> Hence, simple methods of assessing ICP that are non-invasive and repeatable are urgently needed. Early recognition of intracranial hypertension is vital for therapeutic reasons, since a longer duration and increased severity of raised ICP is associated with poor outcome.<sup>[6]</sup> However, a multicentre controlled trial found that treatment of patients with traumatic brain injury based on invasive ICP monitoring was not superior compared with treatment based on clinical examination and CT imaging. No difference in survival, functional and cognitive status, or ICU length of stay was found.<sup>[7]</sup> The authors suggested that monitoring should identify those patients who would benefit from early and specific therapy and prevent patients from being exposed to unnecessary treatments and additional risks. This underlines the need for a simple non-invasive method to detect raised ICP.

Recently, point-of-care ultrasound measurement of the optic nerve sheath diameter (ONSD) has become an alternative approach to assess ICP. The optic nerve sheath is a continuation of the dura mater and the subarachnoid space is extended within the sheath. Thus, the cerebrospinal fluid moves freely between the intracranial and intra-orbital subarachnoid space.<sup>[8]</sup> If the ICP increases, cerebrospinal fluid will fill the subarachnoid space which in turn causes swelling of the optic nerve sheath. This increase in ONSD can be effectively and non-invasively detected by ultrasound. Thereby, ONSD ultrasound could be used to identify elevations in ICP. This is important, since nearly 30% of patients in Europe with traumatic brain injury are managed in non-specialised centres without neurosurgical

facilities.<sup>[9,10]</sup> Furthermore, ONSD ultrasound may be interesting for monitoring ICP in other conditions than traumatic brain injury such as meningitis or hepatic encephalopathy.<sup>[11]</sup> In these situations where CT scanning is difficult or ICP monitoring not possible, ultrasound measurement of ONSD might be a good alternative. The advantage of ultrasound lies in the fact that it can be performed at the bedside without radiation exposure, its non-invasiveness and its repeatability.

This narrative review is part of a series in the Netherlands Journal of Critical Care on ultrasound indications beyond heart and lungs.<sup>[12-14]</sup> In this review, methods for visualising the ONSD using ultrasound and its clinical application will be discussed. Evidence on reproducibility and feasibility will be given and limitations will be listed.

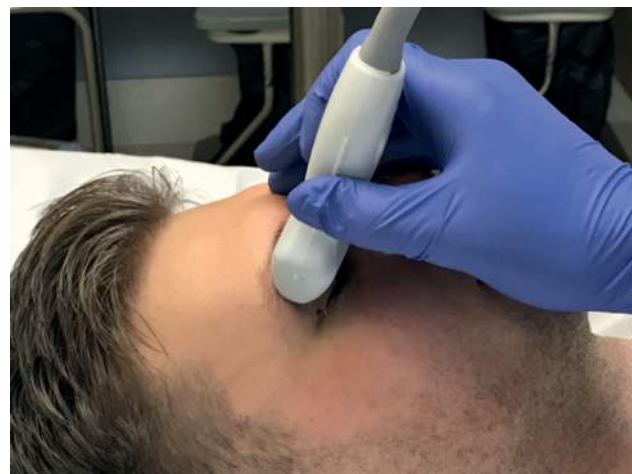### Methods

This is a narrative review. A thorough search in PubMed was conducted to find relevant articles. Two researchers evaluated articles for relevance independently (NT and PRT). MeSH terms such as “diagnostic imaging” or “ultrasonography” or “sonography” and “optic nerve sheath diameter” and “intra cranial pressure” or “intracerebral pressure” or “subarachnoid pressure” were used. Filters were applied to exclude studies that were conducted in animals or patients younger than 18 years. Reference lists of the included articles were screened for selection of additional articles.

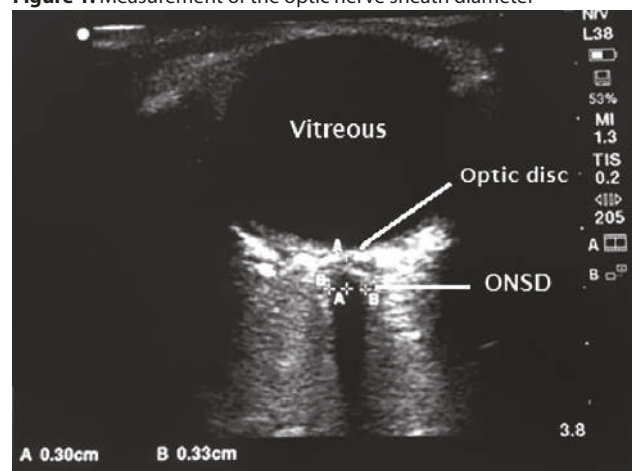
### Image acquisition

A linear transducer is most frequently used, with a frequency range from 5-12 MHz. Small linear probes are preferred as these fit perfectly into the orbit's cavity. The ultrasound machine has to be put in brightness mode.<sup>[15]</sup> The patient usually lies in supine position, head 30 degrees elevated with eyes closed. Both eyes should be examined multiple times. If one eye is injured, perform a single measurement on the unharmed eye. Generally, measurements with the patient in a supine position are mentioned; however, the ONSD does not significantly change with the patient's position.<sup>[16]</sup> The probe is positioned transversally and slightly above the eyelid on the superior and lateral margin of the orbit (*figure 1*). Examination should be performed using a gentle approach. By placing a thick layer of ultrasound gel on the eyelid, unnecessary pressure on the ocular globe, which can cause pain or discomfort such as nausea, vomiting and bradycardia, is prevented. Use of antiseptic ultrasound cream is advised or a clear barrier can be placed over the patient's eyelid. The probe has to be adjusted in order to display the entrance of the optic nerve into the ocular globe and to perform measurement of the optic nerve sheath diameter at 3 mm depth behind the globe,<sup>[15, 17-19]</sup> using the optic disc as a reference point (*figure 2*). The optic nerve appears as a hypoechoic band. The eye should be examined

in both axial and transversal planes, as in some cases a certain probe position offers better views of the optic nerve.<sup>[20]</sup> Axial-plane measurements yielded slightly higher values compared with sagittal plane measurements (median difference 0.15 mm, range 0-0.3 mm).<sup>[21]</sup> The exact number of measurements that should be performed remains unspecified. Goeres et al. demonstrated that a mean of four measurements is more precise (in terms of the measurement with the smallest variance: intraclass correlation coefficient (0.77)) compared with a single measurement.<sup>[22]</sup> Slight rotation of the probe could also offer better visualisation of the optic nerve.



**Figure 1.** Measurement of the optic nerve sheath diameter



**Figure 2.** Ultrasonographic image of the eye and optic nerve system –B =3.3 mm; ONSD = Optic nerve sheath diameter. Measurements are taken 3 mm behind the globe of the eye. This patient had an intracranial pressure of 11 mmHg

### Image interpretation and results

In healthy adults, values of the ONSD measured by ultrasound ranged from 3.68 to 5.4 mm.<sup>[22-25]</sup> Although studies used the same methods for measuring the ONSD, this is a relatively wide range with a difference of up to approximately 32% between

the lowest and highest mean value. One possible explanation might be differences in ethnicities, age and methodology.<sup>[25]</sup> No relationship has been found between ONSD and age, weight or height.<sup>[24, 25]</sup> However, one study did find a sex difference in ONSD, suggesting that previous studies that assessed the normal values of ONSD in healthy adults may have been underpowered to detect a relationship between ONSD and sex.<sup>[22]</sup> Furthermore, conditions such as Graves orbitopathy, inflammation and tumour might alter measurements and influence image interpretations.<sup>[5]</sup>

When studied in patients, ONSD ultrasound was performed either in the emergency department (ED) or in the intensive care unit (ICU). Studies conducted in the ED compared ONSD ultrasound measurements with clinical signs of raised ICP on CT imaging or direct ICP measurements by means of a lumbar puncture, whereas studies in the ICU compared ultrasound ONSD measurements with continuous measurements of ICP with invasive intracranial monitoring devices. Causes of a suspected or truly raised intracranial pressure were divided into traumatic or non-traumatic. One study was conducted in the ED and ICU combined.<sup>[26]</sup> A summary of study characteristics and outcomes of studies on ONSD ultrasound is presented in *table 1*.

For qualitative assessment of a raised ICP, corresponding with an ICP of >20 mmHg, an optimal cut-off value of the ONSD was found to be >5 mm<sup>[5, 18, 26-29]</sup> with a range of 4.7 mm to 5.7 mm.<sup>[21, 30-35]</sup> Midline shift, detected by CT, corresponded with an optimal cut-off value of 5.3 mm ONSD with a sensitivity of 70% and a specificity of 74%, showing that the ONSD was significantly higher in patients with a midline shift compared with patients without midline shift assessed by cranial CT (5.3 mm vs. 4.4;  $p=0.03$ ).<sup>[31]</sup> A significant correlation between ultrasound measurement of the ONSD and the size of midline shift was found ( $r=0.37$ ;  $p=0.01$ ). A recent meta-analysis assessed the diagnostic accuracy of ONSD ultrasound (with a cut-off value of >5 mm) compared with findings of increased ICP on CT imaging. Pooled data demonstrated a sensitivity of 95.6% (95% CI 87.7-98.5%) and a specificity of 92.3% (95% CI 77.9-98.4%).<sup>[36]</sup> Another systematic review compared ONSD ultrasound with invasive ICP monitoring (with an ONSD cut-off value ranging from >5.0-5.9 mm). Pooled sensitivity was 90% (95% CI 80-95%) and pooled specificity was 85% (95% CI 73-93%).<sup>[37]</sup> A new systematic review comparing ONSD ultrasound with either invasive ICP monitoring, CT imaging or lumbar puncture is being conducted and expected to be published soon.<sup>[38]</sup> To determine whether ultrasound measurement of ONSD could serve as a noninvasive surrogate marker for ICP changes, a recent study published in 2018 evaluated the potential of ONSD ultrasound to detect dynamic changes of ICP. They demonstrated that the change in ONSD was strongly correlated with the change in ICP ( $r=0.67$ ; 95% CI 0.34-0.87;  $p<0.001$ ), implying that ONSD ultrasound could dynamically detect changes in ICP.<sup>[39]</sup> Two additional studies also found a strong correlation between ONSD and invasive ICP measurements in patients with brain injury ( $r=0.68$ ;  $r=0.90$ ), respectively.<sup>[5, 34]</sup> Moreover, their results showed

that the ONSD increased and decreased parallel with the ICP; this demonstrated that the ONSD reflects immediate changes in ICP.<sup>[5]</sup> Another study compared different ultrasound-based methods of measuring ICP non-invasively versus invasively. Non-invasive ICP methods included ONSD ultrasound, arterial transcranial Doppler derived methods and straight sinus systolic flow velocity (FVsv). Both ONSD ultrasound and FVsv were correlated with invasive ICP measurements ( $r=0.76$  and  $r=0.72$ ;  $p<0.001$ , respectively). Moreover, the combination of ONSD ultrasound and FVsv resulted in a stronger correlation with invasive ICP measurements ( $r=0.81$ ).<sup>[40]</sup> One study investigated the effect of osmotherapy on ONSD and whether ONSD decreases simultaneously with ICP during treatment of elevated ICP with mannitol infusion (osmotherapy).<sup>[41]</sup> The authors found a statistically significant correlation between ONSD and ICP before and after treatment with mannitol ( $r^2=0.54$ ;  $p<0.002$ ). Furthermore, ONSD and ICP significantly decreased after mannitol infusion. The median values of ICP and ONSD were 35 mmHg (IQR 32-41) and 6.3 mm (IQR 6.1-6.7), respectively. These rates decreased significantly after mannitol infusion to 25 mmHg (IQR 22-29;  $p=0.001$ ) and 5.7 mm (5.5-6.3;  $p=0.0007$ ), respectively.<sup>[41]</sup> Lastly, no complications from ONSD ultrasound were reported in the included studies.

In summary, it can be concluded that ONSD ultrasound used as a qualitative measurement of increased ICP is a sensitive, specific, accurate and safe method to detect increased ICP. Whether ultrasound measurement of ONSD is a qualitative rather than quantitative measurement, and thus can replace continuous ICP monitoring, remains a matter of debate. Maissan et al. mentioned that the distension response of the optic nerve sheath depends on its elasticity. This elasticity varies among individuals and therefore, ONSD ultrasound is a quantitative rather than a qualitative tool to assess ICP.<sup>[5]</sup> The use of ONSD ultrasound as a quantitative tool exemplifies a method to dynamically evaluate the ICP, which is currently done by invasive ICP monitoring. In line with the study results of Wang et al. and Soldatos et al. the potential of ONSD ultrasound to detect dynamic changes in ICP seems very promising.<sup>[34, 39]</sup> However, despite the strong correlation found, direct changes in ONSD did correspond with a wide range in ICP values. For example: in the study by Wang et al. a change in ONSD of approximately 0.5 mm corresponded with ICP values ranging from less than 50 mmH<sub>2</sub>O up to almost 200 mmH<sub>2</sub>O.<sup>[39]</sup> This wide range in corresponding ICP values was also seen in the study by Soldatos et al.<sup>[34]</sup> Therefore, ONSD ultrasound should not yet be used as a marker for dynamic changes in ICP and further investigation is warranted.

### Is optic nerve ultrasound reproducible, feasible and easy to learn?

Only few studies have studied the repeatability (intraobserver variability) and reproducibility (interobserver variability) of ONSD ultrasound. High rates of repeatability were found in

**Table 1.** Characteristics and outcomes of studies assessing ultrasound measurement of optical nerve sheath diameter

CT = computed tomography; ED = emergency department; ICU = intensive care unit; ICP = intracranial pressure; LP = lumbar puncture; NEU = department of neurology and ophthalmology; NM = not mentioned; ONSD = optical nerve sheath diameter; US = ultrasound

\* Sensitivity and specificity by a given cutoff value for detection of a raised ICP (ICP > 20 H2O) seen on invasive ICP measurements or in cranial CT imaging

Author	Study design and year	Study population and clinical setting	Ultrasound probe	Number of operator(s) and experience	Reference standard	Cut-off value of ONSD (mm)	Sensitivity and specificity of US-ONSD*
Moretti et al. <sup>[21]</sup>	Prospective observational study 2009	63 patients requiring invasive ICP monitoring - ICU	7.5 MHz probe	Experienced operators – at least 60 prior ONSD measurements	Invasive ICP monitoring	5.2	Sensitivity: 93.1% (95% CI: 77.2-99%) Specificity: 73.9% (95%CI: 61.5-84%)
Blaivas et al. <sup>[18]</sup>	Prospective blinded observational study - 2003	14 patients included with proven elevated ICP on CT-imaging (due to intracranial hemorrhage either because of trauma or spontaneous) - ED	10 MHz linear array probe	n=5 –experience ranged from 100-1000 examinations	CT	5.0	Sensitivity: 100% Specificity: 95%
Tayal et al. <sup>[28]</sup>	Prospective blinded observational study - 2007	59 patients with suspected intracranial injury and possible increase of ICP (traumatic head injury)- ED	7.5 MHz linear array probe	NM	CT	5.0(mean binocular ONSD)	Sensitivity: 100 % (95% CI: 68-100%) Specificity: 63% (95% CI: 50-76%)
Kimberly et al. <sup>[26]</sup>	Prospective blinded observational study - 2008	15 patients who had placement of invasive monitoring of ICP (all causes) – ICU / ED	10-5 MHz linear array probe	N=.; - 3 years' experience – 60 examinations of ocular US	Invasive ICP monitoring	5.0	Sensitivity: 88% (95% CI 47-99%) Specificity: 93% (95% CI 78-99%)
Soldatos et al. <sup>[34]</sup>	Prospective observational study - 2008	76 patients - ICU	9 MHz linear array probe	Experienced operator - undefined	Invasive ICP monitoring	5.7	Sensitivity: 74% Specificity: 100%
Major et al. <sup>[29]</sup>	Prospective observational study - 2010	26 patients with a suspicion of increased ICP (all causes) - ED	7.5 MHz probe	5 performed ONSD-measurements before	CT	5.0	Sensitivity: 86% (95% CI 42-99%) Specificity: 100% (95% CI 79-100%)
Rajajee et al. <sup>[32]</sup>	Prospective blinded observational study - 2011	65 patients who had placement of invasive monitoring of ICP (all causes) - ICU	13-6 MHz linear array probe	3 years (main operator) 2 months (second operator)	Invasive ICP monitoring	4.8	Sensitivity: 96% (95% CI 91-99%) Specificity: 94% (95% CI 92-96%)
Frumin et al. <sup>[30]</sup>	Prospective blinded observational study - 2013	27 patients who had placement of invasive monitoring of ICP (all causes) – ICU	10-5 MHz linear array probe	3 year's ultrasonography experience – 250 examinations of ocular US	Invasive ICP monitoring	5.2	Sensitivity: 83.3% (95% CI 35 – 99.6%) Specificity: 100% (95% CI 83.9 – 100%)
Amini et al. <sup>[33]</sup>	Descriptive prospective study - 2013	50 patients of whom 14 had an elevated ICP ED	7.5 MHz linear array probe	Senior resident who had been trained by a radiologist	LP	5.5	Sensitivity: 100% (95% CI 100-100) Specificity: 100% (95% CI 100-100)
Golshani et al. <sup>[27]</sup>	Diagnostic trial - 2015	131 patients with suspected elevated ICP (all causes) - ED	7.5 MHz linear array probe	NM	CT	5.0	Sensitivity: 100% (95% CI: 84.0-100.0%) Specificity: 31.9% (95%CI: 23-41.7%)
Maissan et al. <sup>[5]</sup>	Prospective observational study - 2015	18 patients who suffered traumatic brain injury - ICU	7.5 MHz linear array probe	NM	Invasive ICP monitoring	5.0	Sensitivity: 94% Specificity: 98%
Komut et al. <sup>[31]</sup>	Prospective observational study - 2016	100 patients with non-traumatic intracranial injury - ED	11-14 MHz probe	NM	CT	4.7	Sensitivity: 70% Specificity: 86%
Liu et al. <sup>[35]</sup>	Prospective observational study - 2017	110 patients who were suspected of an elevated ICP - NEU	NM	Experienced operator - undefined	LP	5.6	Sensitivity: 86% Specificity: 73%

two studies, showing an intraobserver agreement (analysed by Cronbach's alpha) with a range of 0.69-0.72,<sup>[42]</sup> and 0.92-0.97,<sup>[43]</sup> respectively. Reproducibility was also high among several studies, demonstrating mean differences in measurements between observers ranging from 0.01 mm to 0.30 mm.<sup>[21, 34, 39, 43, 44]</sup> Although these differences between observers seem minimal, it may correlate with significant differences in ICP values, hence these results have to be interpreted carefully.

Feasibility has not been studied in particular, most studies did not mention cases where ultrasound measurement of ONSD was not feasible. One study mentioned a 100% success rate of ultrasound ONSD.<sup>[19]</sup>

Literature concerning the learning curve of ONSD ultrasound is limited. The learning curve seems rapid and depends on the ultrasound experience of the operator. One study examined

the learning curve for ultrasound assessment of ONSD and concluded that, to obtain adequate results, ten examinations including three abnormal scans are needed for experienced operators and 25 scans for less experienced operators. However, the authors did not elaborate on how they calculated this estimated learning curve.<sup>[28]</sup> Another study also examined the learning curve for ONSD ultrasound, and found that the within-subject variance reached a plateau after the 21st measurement. The authors critically reviewed the results and suggested that this may not be the true learning curve as the operator was already experienced with this technique. However, they also developed a unique statistical model to determine the learning curve of ONSD ultrasound, so future studies could use this model when studying the learning curve of ONSD ultrasound.<sup>[45]</sup>

### Limitations

Given the impact of increased ICP on patient outcome, nearly perfect accuracy of ONSD ultrasound is of critical importance. More specifically, accurate dynamic evaluation of ICP is of clinical relevance since fluctuations are common in patients with acute brain injury and in particular in patients who receive treatments which need to be monitored and evaluated continuously, such as when to assess the effect of ICP-lowering treatments.<sup>[8]</sup> While on average data on ONSD ultrasound seem to be accurate, a more careful evaluation of data may be a cause for concern. For example, one study found a significant decrease in the accuracy of ONSD ultrasound in the presence of acute fluctuations of ICP. When ICP fluctuated above and below 20 mmHg within a cluster of six measurements, a decrease in specificity of 24% (98% to 74%) and a positive predictive value of 13% (89% to 76%) was seen.<sup>[8]</sup> A possible explanation is the delayed response of reversibility of the ONSD distension. Also, when assessing changes in ONSD by ultrasound, changes less than 0.5 mm have to be accurately assessed, while most ultrasound probes have a smallest measurable distance of 0.1 mm, which can equal over 20% of this change. Other reasons why ultrasound measurement of ONSD to detect increased ICP is still limited in current practice are: (1) there is no consensus regarding the optimal cut-off value for ONSD to detect an increased ICP, which could be due to different patient populations, variability in operator's experience and learning curves, and different reference standards, e.g. studies in the ED were using CT imaging or lumbar puncture as reference whereas studies in the ICU were using invasive ICP monitoring as a reference standard; (2) a considerable range in the size of study populations and different methodological approaches; and (3) some included only traumatic brain injuries whereas others included all possible causes of increased ICP.

### Conclusion and future directions

The study results demonstrate that ONSD ultrasound is a sensitive and specific method for detecting an increased ICP. As for the future, the following issues have to be considered: (1) more data

on ONSD ultrasound are needed in order to come to agreement on both the normal values of ONSD and the optimal ONSD cut-off value; (2) effects of ICP monitoring by ONSD ultrasound on patient outcome should be studied; (3) a (mathematical) model which could determine an accurate value of ICP by measuring the change in ONSD is needed; (4) there is a learning curve for ONSD ultrasound for both operators who are inexperienced with ultrasound and for operators who already have ultrasound experience yet for different applications. Considering the benefits of ultrasound mentioned above, together with the potential of ONSD ultrasound as a modality to accurately predict changes in ICP, the next big step is to further refine and ultimately implement this into the daily routine of ICU care, thereby protecting patients from complications and downsides of current diagnostic modalities.

For now, assessment of ONSD by ultrasound may serve as an additional diagnostic tool to diagnose a raised ICP. However, ONSD ultrasound is not ready to serve as an alternative diagnostic modality when invasive ICP evaluation is not available or contraindicated, such as trauma scenes or follow-up of patients with acute liver failure. Furthermore, ONSD ultrasound may serve as a modality to screen patients who probably need continuous invasive ICP monitoring. We advise that assessment of increased ICP values should not be done by ONSD ultrasound alone and should always be assessed together with available data from clinical examination and other diagnostic modalities.

### Disclosures

All authors declare no conflict of interest. No funding or financial support was received.

### References

1. Stocchetti N, Maas AIR. Traumatic Intracranial Hypertension. *New England Journal of Medicine*. 2014;370(22):2121-30.
2. Guiza F, Depreitere B, Piper I, Citerio G, Chambers I, Jones PA, et al. Visualizing the pressure and time burden of intracranial hypertension in adult and paediatric traumatic brain injury. *Intensive care medicine*. 2015;41(6):1067-76.
3. Citerio G, Bakker J, Bassetti M, Benoit D, Cecconi M, Curtis JR, et al. Year in review in *Intensive Care Medicine* 2014: I. Cardiac dysfunction and cardiac arrest, ultrasound, neurocritical care, ICU-acquired weakness, nutrition, acute kidney injury, and miscellaneous. *Intensive care medicine*. 2015;41(2):179-91.
4. Aduayi OS, Asaley CM, Adetiloye VA, Komolafe EO, Aduayi VA. Optic nerve sonography: A noninvasive means of detecting raised intracranial pressure in a resource-limited setting. *Journal of Neurosciences in Rural Practice*. 2015;6(4):563-7.
5. Maissan IM, Dirven PJ, Haitisma IK, Hoeks SE, Gommers D, Stolker RJ. Ultrasonographic measured optic nerve sheath diameter as an accurate and quick monitor for changes in intracranial pressure. *Journal of neurosurgery*. 2015;123(3):743-7.
6. Stocchetti N, Maas AIR. Traumatic Intracranial Hypertension. *New England Journal of Medicine*. 2014;370(22):2121-30.
7. Chesnut RM, Temkin N, Carney N, Dikmen S, Rondina C, Videtta W, et al. A Trial of Intracranial-Pressure Monitoring in Traumatic Brain Injury. *New England Journal of Medicine*. 2012;367(26):2471-81.
8. Rajajee V, Fletcher JJ, Rochlen LR, Jacobs TL. Comparison of accuracy of optic nerve ultrasound for the detection of intracranial hypertension in the setting of acutely fluctuating vs stable intracranial pressure: post-hoc analysis of data from a prospective, blinded single center study. *Critical care (London, England)*. 2012;16(3):R79.
9. Patel HC BO, Woodford M, King AT, Yates DW, Lecky FE. Trends in head injury outcome from 1989 to 2003 and the effect of neurosurgical care: an observational study. *The Lancet*. 2005;4:366(9496):1538-44.
10. Geeraerts T, Duranteau J, Benhamou D. Ocular sonography in patients with raised intracranial pressure: the papilloedema revisited. *Critical Care*. 2008;12(3):150.

11. Bordes J, Boret H, Lacroix G, Prunet B, Meaudre E, Kaiser E. Decompressive craniectomy guided by cerebral microdialysis and brain tissue oxygenation in a patient with meningitis. *Acta Anaesthesiologica Scandinavica*. 2011;55(1):130-3.
12. M.E. Haaksma LA, L.Heunks, A.Spoelstra-de Man, PR. Tuinman. Ultrasound imaging of the diaphragm: facts and future. A guide for the bedside clinician. *Netherlands Journal of Critical Care*. 2018;26(2):58-63.
13. F.H. Bosch PRT. The golden age of ultrasound is only just beginning. *Netherlands Journal of Critical Care*. 2018;26(2):56-7.
14. J.E. Lopez Matta CVEK, D.J. van Westerloo. To see or not to see: ultrasound-guided percutaneous tracheostomy. *Netherlands Journal of Critical Care*. 2018;56(2):66-9.
15. Hansen HC, Helmke K, Kunze K. Optic Nerve Sheath Enlargement in Acute Intracranial Hypertension. *Neuro-Ophthalmology*. 1994;14(6):345-54.
16. Romagnuolo L, Tayal V, Tomaszewski C, Saunders T, Norton HJ. Optic nerve sheath diameter does not change with patient position. *The American journal of emergency medicine*. 2005;23(5):686-8.
17. Toscano M, Spadetta G, Pulitano P, Rocco M, Di Piero V, Mecarelli O, et al. Optic Nerve Sheath Diameter Ultrasound Evaluation in Intensive Care Unit: Possible Role and Clinical Aspects in Neurological Critical Patients' Daily Monitoring. *BioMed research international*. 2017;2017:1621428.
18. Blaivas M, Theodoro D, Sierzenski PR. Elevated intracranial pressure detected by bedside emergency ultrasonography of the optic nerve sheath. *Academic emergency medicine : official journal of the Society for Academic Emergency Medicine*. 2003;10(4):376-81.
19. Geeraerts T, Merceron S, Benhamou D, Vigue B, Duranteau J. Non-invasive assessment of intracranial pressure using ocular sonography in neurocritical care patients. *Intensive care medicine*. 2008;34(11):2062-7.
20. Kilker BA, Holst JM, Hoffmann B. Bedside ocular ultrasound in the emergency department. *European journal of emergency medicine : official journal of the European Society for Emergency Medicine*. 2014;21(4):246-53.
21. Moretti R, Pizzi B, Cassini F, Vivaldi N. Reliability of optic nerve ultrasound for the evaluation of patients with spontaneous intracranial hemorrhage. *Neurocritical care*. 2009;11(3):406-10.
22. Goeres P, Zeiler FA, Unger B, Karakitsos D, Gillman LM. Ultrasound assessment of optic nerve sheath diameter in healthy volunteers. *Journal of Critical Care*. 2016;31(1):168-71.
23. Bäuerle J, Schuchardt F, Schroeder L, Egger K, Weigel M, Harloff A. Reproducibility and accuracy of optic nerve sheath diameter assessment using ultrasound compared to magnetic resonance imaging. *BMC Neurology*. 2013;13(1):187.
24. Maude RR, Amir Hossain M, Hassan MU, Osbourne S, Sayeed KLA, Karim MR, et al. Transorbital Sonographic Evaluation of Normal Optic Nerve Sheath Diameter in Healthy Volunteers in Bangladesh. *PLoS ONE*. 2013;8(12):e81013.
25. Chen H, Ding G-S, Zhao Y-C, Yu R-G, Zhou J-X. Ultrasound measurement of optic nerve diameter and optic nerve sheath diameter in healthy Chinese adults. *BMC Neurology*. 2015;15(1):106.
26. Kimberly HH, Shah S, Marill K, Noble V. Correlation of optic nerve sheath diameter with direct measurement of intracranial pressure. *Academic emergency medicine : official journal of the Society for Academic Emergency Medicine*. 2008;15(2):201-4.
27. Golshani K, Ebrahim Zadeh M, Farajzadegan Z, Khorvash F. Diagnostic Accuracy of Optic Nerve Ultrasonography and Ophthalmoscopy in Prediction of Elevated Intracranial Pressure. *Emergency (Tehran, Iran)*. 2015;3(2):54-8.
28. Tayal VS, Neulander M, Norton HJ, Foster T, Saunders T, Blaivas M. Emergency department sonographic measurement of optic nerve sheath diameter to detect findings of increased intracranial pressure in adult head injury patients. *Annals of emergency medicine*. 2007;49(4):508-14.
29. Major R, Girling S, Boyle A. Ultrasound measurement of optic nerve sheath diameter in patients with a clinical suspicion of raised intracranial pressure. *Emergency medicine journal : EMJ*. 2011;28(8):679-81.
30. Frumin E, Schlang J, Wiechmann W, Hata S, Rosen S, Anderson C, et al. Prospective analysis of single operator sonographic optic nerve sheath diameter measurement for diagnosis of elevated intracranial pressure. *The western journal of emergency medicine*. 2014;15(2):217-20.
31. Komut E, Kozaci N, Sonmez BM, Yilmaz F, Komut S, Yildirim ZN, et al. Bedside sonographic measurement of optic nerve sheath diameter as a predictor of intracranial pressure in ED. *The American journal of emergency medicine*. 2016;34(6):963-7.
32. Rajajee V, Vanaman M, Fletcher JJ, Jacobs TL. Optic nerve ultrasound for the detection of raised intracranial pressure. *Neurocritical care*. 2011;15(3):506-15.
33. Amini A, Kariman H, Arhami Dolatabadi A, Hatamabadi HR, Derakhshanfar H, Mansouri B, et al. Use of the sonographic diameter of optic nerve sheath to estimate intracranial pressure. *The American journal of emergency medicine*. 2013;31(1):236-9.
34. Soldatos T, Karakitsos D, Chatzimichail K, Papathanasiou M, Gouliamos A, Karabinis A. Optic nerve sonography in the diagnostic evaluation of adult brain injury. *Critical Care*. 2008;12(3):R67.
35. Liu D, Li Z, Zhang X, Zhao L, Jia J, Sun F, et al. Assessment of intracranial pressure with ultrasonographic retrobulbar optic nerve sheath diameter measurement. *BMC Neurology*. 2017;17(1):188.
36. Ohle R, McIsaac SM, Woo MY, Perry JJ. Sonography of the Optic Nerve Sheath Diameter for Detection of Raised Intracranial Pressure Compared to Computed Tomography: A Systematic Review and Meta-analysis. *Journal of ultrasound in medicine : official journal of the American Institute of Ultrasound in Medicine*. 2015;34(7):1285-94.
37. Dubourg J, Javouhey E, Geeraerts T, Messerer M, Kassai B. Ultrasonography of optic nerve sheath diameter for detection of raised intracranial pressure: a systematic review and meta-analysis. *Intensive care medicine*. 2011;37(7):1059-68.
38. Koziaz A, Sne N, Kegel F, Alhazzani W, Nath S, Badhiwala JH, et al. Optic nerve sheath diameter sonography for the diagnosis of increased intracranial pressure: a systematic review and meta-analysis protocol. *BMJ Open*. 2017;7(8):e016194.
39. Wang L, Chen L, Chen Y, et al. Ultrasonography assessments of optic nerve sheath diameter as a noninvasive and dynamic method of detecting changes in intracranial pressure. *JAMA Ophthalmology*. 2018.
40. Robba C, Cardim D, Tajsic T, Pietersen J, Bulman M, Donnelly J, et al. Ultrasound non-invasive measurement of intracranial pressure in neurointensive care: A prospective observational study. *PLoS medicine*. 2017;14(7):e1002356.
41. Launey Y, Nessler N, Le Maguet P, Malledant Y, Seguin P. Effect of osmotherapy on optic nerve sheath diameter in patients with increased intracranial pressure. *Journal of neurotrauma*. 2014;31(10):984-8.
42. Lochner P, Coppo L, Cantello R, Nardone R, Naldi A, Leone MA, et al. Intra- and interobserver reliability of transorbital sonographic assessment of the optic nerve sheath diameter and optic nerve diameter in healthy adults. *Journal of ultrasound*. 2016;19(1):41-5.
43. Bäuerle J, Lochner P, Kaps M, Nedelmann M. Intra- and interobserver reliability of sonographic assessment of the optic nerve sheath diameter in healthy adults. *Journal of neuroimaging : official journal of the American Society of Neuroimaging*. 2012;22(1):42-5.
44. Ballantyne SA, O'Neill G, Hamilton R, Hollman AS. Observer variation in the sonographic measurement of optic nerve sheath diameter in normal adults. *European journal of ultrasound : official journal of the European Federation of Societies for Ultrasound in Medicine and Biology*. 2002;15(3):145-9.
45. Zeiler FA, Ziesmann MT, Goeres P, Unger B, Park J, Karakitsos D, et al. A unique method for estimating the reliability learning curve of optic nerve sheath diameter ultrasound measurement. *Critical ultrasound journal*. 2016;8(1):9.