

## CASE REPORT

# Beriberi in the ICU: remarkable shock reversal with thiamine

R.M. van Stigt<sup>1</sup>, G. van der Wal<sup>1</sup>, S. Kamphuis<sup>2</sup>, A. Braber<sup>1</sup>

<sup>1</sup>Department of Intensive Care Medicine, Gelre Hospital, Apeldoorn, the Netherlands

<sup>2</sup>Department of Clinical Chemistry, Gelre Hospital, Apeldoorn, the Netherlands

## Correspondence

R.M. van Stigt - r.vanstigt@gmail.com

**Keywords** - thiamine deficiency, shock, beriberi

## Abstract

Wet and dry beriberi are two clinical manifestations of thiamine deficiency, and beriberi with fulminant cardiovascular collapse is called Shoshin beriberi. It can present as shock with high levels of lactate and a need for high doses of vasopressor therapy, in which thiamine infusion can effectuate rapid cardiovascular and respiratory recovery. This is not often considered in the differential diagnosis of profound shock but thiamine deficiency is more prevalent than oftentimes thought, and therefore we present two cases of Shoshin beriberi in our intensive care unit with thiamine-mediated shock reversal. Both patients were malnourished, had demonstrably low thiamine levels, and showed marked recovery upon infusion of thiamine.

## Introduction

Thiamine is a water-soluble vitamin, which is able to cross the blood-brain barrier. Once absorbed into the blood from the duodenum, it is bound to albumin. It can be stored in the liver for a maximum of 18 days, and is converted in the cellular cytosol into its active form, thiamine pyrophosphate (TPP), by thiamine diphosphotransferase. TPP is a cofactor in several cellular processes, as illustrated in *figure 1*. It is not only important in the generation of adenosine triphosphate (ATP) to fuel cellular processes, but also in lipid metabolism to form myelin sheaths in neuronal cells and the production of neurotransmitters and amino acids (*figure 1*).<sup>[1,2]</sup> Body stores of thiamine are low and have a short half-life, so a deficiency can occur quickly. Thiamine deficiency can slow down the production of ATP through aerobic metabolism and can force other mechanisms of glucose metabolism to occur. It has been associated with metabolic acidosis, sepsis and septic shock, neurodegeneration, cardiac failure and refeeding syndrome.<sup>[2]</sup>

Causes of thiamine deficiency and the patients who are at risk are mentioned in *table 1*.<sup>[3-5]</sup> ICU patients are among those at risk for thiamine deficiency.

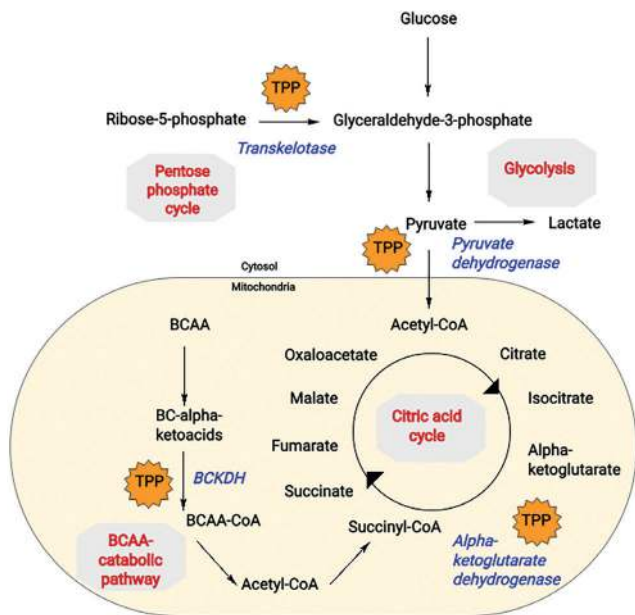
**Table 1.** Patient categories at risk for thiamine deficiency

Causes of thiamine deficiency	
Malnourishment	Alcohol abuse Other substance (e.g. opioid) abuse Excessive emesis Eating disorders Institutionalisation (e.g. prison) High-carbohydrate, low-nutrition diet
Increased loss	Diuretic therapy Renal failure treated with dialysis
Decreased uptake	Post gastro-enteric surgery
Increased demand	Pregnancy Lactation Hyperthyroidism Systemic infections/sepsis Critical illness
Institutionalisation (e.g. prison)	Elderly

This makes attention to the thiamine status in these patients important. Symptomatic thiamine deficiency can cause several clinical syndromes, one of which is known as beriberi. Dry beriberi is the development of a symmetrical peripheral neuropathy characterised by sensory and motor impairments, mostly of the distal extremities. Wet beriberi includes cardiac involvement: it begins with systemic vasodilation, which leads to fluid and salt retention and thus peripheral oedema. The resulting fluid overload stresses the heart, possibly leading to overuse injury and resulting in tachycardia, dyspnoea and chest pain. If the clinical course is fulminant, it is called Shoshin beriberi from the Japanese Sho (acute damage) Shin (heart). This is caused by a primary insult to the heart and leads to a low-output state, sometimes combined with peripheral vasodilatation.<sup>[6,7]</sup> This disease was first reported more than 1000 years ago, and eventually led to the discovery of vitamin B1: thiamine.<sup>[8]</sup> Another manifestation of thiamine deficiency is Wernicke-Korsakoff syndrome, two conditions with one evolving from the other. Early on, Wernicke is an encephalopathy which can present with ataxia, ophthalmoplegia, balance abnormalities and altered mental status. Korsakoff is

the evolution of untreated Wernicke and involves delirium and permanent memory loss.<sup>[2]</sup> All of these syndromes are treated with thiamine suppletion.

Shoshin beriberi is often not considered in the differential diagnosis of severe shock. It is a rare presentation of thiamine deficiency, but one with severe consequences when not recognised. We will present two cases to illustrate the importance of considering and treating beriberi in acutely ill patients.



**Figure 1.** The role of thiamine pyrophosphate (TPP) in metabolic pathways

CoA = coenzyme A, BCAA = branched chain amino acids, BCKDH = branched chain alpha-ketoacid dehydrogenase complex. Enzymes are italicised, metabolic pathways are in bold. Based on a figure from Oregon State University: <https://lpi.oregonstate.edu/mic/vitamins/thiamin>

**Case reports**

*Patient 1*

The first patient is a homeless 57-year-old woman with a history of cocaine and methadone abuse, gastroparesis, cervical carcinoma, iron deficiency anaemia, chronic kidney injury stage III, active hepatitis C and prior hepatitis B. She presented to our emergency department (ED) with a history of progressive dyspnoea.

Upon arrival to the ED, she had a respiratory rate of 38/min with an SpO<sub>2</sub> of 94%, dropping to 77% despite a non-rebreathing mask with 15 l/min of oxygen. Lung sounds were normal, but the patient was using all her accessory ventilatory muscles. Blood pressure was 80/50 mmHg with a heart rate of 94 beats/min; the extremities were cyanotic and pale. She was cachectic, moved all her extremities symmetrically and was agitated. Her body temperature was 34.3°C and body mass index was 14.5 kg/

m<sup>2</sup>. Her chronic medication included methadone, transdermal fentanyl, pantoprazole and metoclopramide. Intoxications consisted of cocaine, but not alcohol.

Chest X-ray showed pronounced vascular markings and Kerley B lines. The results of the laboratory tests are summarised in *table 2*. The ECG showed sinus rhythm of 96 beats/min.

On admission to the ICU, she was intubated, ventilated and resuscitated with crystalloids and supported with milrinone and norepinephrine, warmed with a hot air warming blanket, and started on high-volume continuous venovenous haemofiltration (CVVH). In accordance with our standard of care, 300 mg of thiamine was administered intravenously as well as antibiotic and steroid therapy.<sup>[9]</sup>

Clinically, this patient had high systemic vascular resistance (SVR) and low output. Differential diagnostic considerations included gastrointestinal ischaemia and cardiogenic shock; sepsis seemed unlikely because of the absence of inflammatory markers. Computed tomography angiography (CTA) of the abdomen ruled out gastrointestinal ischaemia and an emergency transthoracic echocardiogram (TTE) showed a moderately to severely reduced left ventricular ejection fraction (LVEF) ('eyeballing'), no pericardial effusion, and no regional wall motion abnormalities.

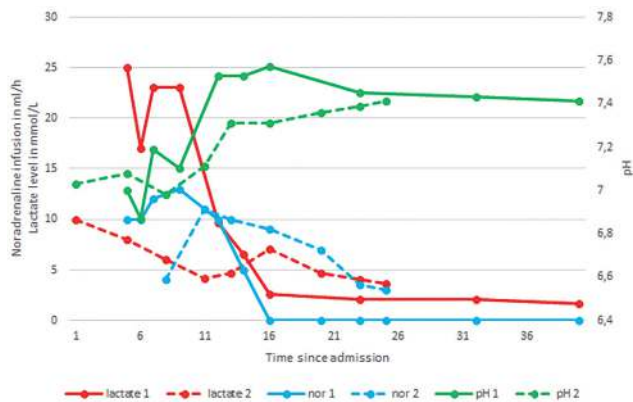
**Table 2.** Relevant laboratory values for both patients at admission

Laboratory at admission	Patient 1	Patient 2	Normal value
C-reactive protein	5.3	467	<10 mg/l
Leukocytes	9.2	5.8	4-10/nl
Blood urea nitrogen	15.2	13.6	2.5-7.5 mmol/l
Creatinine	183	371	50-100 µmol/l
Arterial blood gas			
pH	7.0	7.03	7.35-7.45
pCO <sub>2</sub>	2.5	1.7	4.7-6.1 kPa
HCO <sub>3</sub>	5	3	21-26 mmol/l
base excess	-24.4	-25.2	-2 to 3 mmol/l
O <sub>2</sub> saturation	99	96	>97%
pO <sub>2</sub>	35.8	14.1	10-13 kPa
Lactate	25	10	0.6-0.9 mmol/l

Within 28 hours, the inotropic and vasopressor agents and high-volume CVVH were discontinued and the patient was extubated (*figure 2*). Her thiamine level was 48 nmol/l (66-200 nmol/l, whole blood, before suppletion), upon which thiamine was continued at 100 mg daily. Pragmatically, vitamin B12 was also supplemented. Forty-two hours after admission to the ICU, she was transferred to the internal medicine ward.

An echocardiogram five days after admission showed normal ventricular dimensions, LVEF of 25-30%, and diastolic dysfunction grade 3.

During her stay in the internal medicine department, she failed to gain weight, displaying behaviour consistent with an eating disorder, possibly exacerbated by her gastroparesis due to methadone use or hepatitis C.



**Figure 2.** Key values for both patients

Time since admission in hours, T4 is admission to our ICU (patient 2 was transferred from another location). Thiamine was administered at T4. Noradrenaline infusion in ml/h of a 0.2 mg/ml solution

### Patient 2

Our second patient is a 76-year-old woman with a history of non-insulin-dependent diabetes mellitus, hypertension, small-cell lung carcinoma for which she had undergone four chemotherapy sessions (the latest, two weeks before admission). She presented to our ED with dyspnoea. She was nauseous but not vomiting and complained of difficulty in eating. Her chronic medication included amlodipine, metformin and tolbutamide. The patient was alert, showed tachypnoea (30-40 breaths/min), diffuse rhonchi on chest auscultation, and an SpO<sub>2</sub> of 93% on room air. Her heart rate was irregular at 150-200 beats/min, RR was 150/90 mmHg, and her extremities were rather cold the core temperature was normal.

The chest X-ray was unremarkable. Laboratory studies are summarised in *table 1*. ECG showed atrial flutter with a ventricular rate 191 beats/min and no evidence of ST-segment changes.

Urgent fluid resuscitation was started and she was transferred to our ICU, where she was intubated and started on noradrenaline, milrinone and continuous venovenous haemofiltration (CVVH). TTE showed normal dimensions and function of the left and right ventricles without wall motion abnormalities.

Differential diagnostic considerations for this patient included metformin-associated lactate acidosis, septic shock, pulmonary embolism, and hypovolaemia after a period of anorexia. Pulmonary embolism and infiltrative changes were ruled out by CTA of the thorax, and hypovolaemia was corrected with fluid administration. There were no indicators of cardiac ischaemia (low troponins and no suggestive ECG changes).

Twenty-two hours after admission to the ICU, vasopressors could be discontinued after rapid stabilisation of the haemodynamics. Because of this, thiamine deficiency was considered as the cause of her metabolic acidosis and multiple organ dysfunction. Before suppletion the thiamine was 28 nmol/l (66-200 nmol/l, whole blood), and it had been supplemented upon admission. After 50

hours, the patient was extubated and after 69 hours CVVH was discontinued (*figure 2*). Blood and sputum cultures remained negative, polymerase chain reaction of para-influenza was positive. ICU stay was extended due to an ST-segment elevation myocardial infarction (STEMI) acute coronary syndrome (ACS) with inferoseptal and anteroseptal hypokinesia on the echocardiogram on day 4. After a total hospital stay of 30 days, she finished her chemotherapy as an outpatient.

### Discussion

The cases we have reported show the importance of recognising and treating thiamine deficiency in the ICU. Neither of the patients had a history of alcoholism, and both suffered profound shock with severe lactate acidosis and multiple organ dysfunction. Both patients showed rapid stabilisation after administration of 300 mg of thiamine and had thiamine levels below the reference levels making the diagnosis of Shoshin beriberi very likely. No other explanations for their profound shock were found.

Patient 1 still had an impaired LVEF on day 5; the recovery time of LVEF after Shoshin beriberi is not known. It is possible that she had pre-existent cardiomyopathy (caused by her substance abuse or entirely unrelated), exacerbated by this episode of beriberi. Patient 2 had high inflammatory parameters, caused by a para-influenza infection. She developed cardiac decompensation with ST-segment changes and apicoseptal hypokinesia several days after admission, possibly secondary to shock or as a complication of Shoshin beriberi; follow-up myocardial SPECT showed <5% of reversible ischaemia. The prognosis of beriberi cardiomyopathy is generally good when thiamine is supplemented at the appropriate moment; it can bring about a rapid stabilisation of haemodynamic parameters. Patients who had thiamine deficiency at admission to the ICU showed faster lactate level reduction and a reduction of mortality over time with thiamine treatment.<sup>[10]</sup>

Both our patients had rapid decreases in lactate levels, possibly accelerated by CVVH. Patient 1 showed an initial lowering of the lactate level before it rose and fell once again; this remains unexplained. She had not received any vitamin suppletion in the emergency department. A possible explanation is the amount of intravenous fluids the patient had received during initial resuscitation, diluting the lactate level or correcting a hypovolaemic component in the patient's illness. This is supported by a drop in the haemoglobin level from 5.6 to 4.7 in 75 minutes without active bleeding.

Among the patients admitted to ICUs, there are several groups at risk for thiamine deficiency, as referenced in *table 1*. The incidence of thiamine deficiency in our ICU is almost 40% in patients treated with intensive insulin therapy, and therefore it is standard of care in our centre to infuse 300 mg of thiamine upon admission of a patient with an expected ICU stay >48 hours.<sup>[9]</sup> There have been reports

of Shoshin beriberi with profound shock with multiple organ dysfunction and lactataemia which was rapidly reversed after infusion of thiamine, usually within 1-12 hours, with cessation of respiratory and haemodynamic support within 2-48 hours.<sup>[3,6,10-12]</sup> In those with myocardial and pulmonary insufficiency in the ICU, the administration of intravenous thiamine was associated with a rise in blood pressure and central venous pressure without elevation of the heart rate.<sup>[5]</sup> Thiamine has no known severe side effects.

In the treatment of severely compromised patients who are at risk for thiamine depletion, it is important to give thiamine before infusion of glucose: without thiamine, pyruvate cannot enter the citric acid cycle and thus ATP production stops at the conversion of pyruvate to lactate, exacerbating lactic acidosis and yielding less ATP per molecule of glucose metabolised (*figure 1*).

In clinical practice, it is advisable to consider and, if possible, measure a patient's thiamine status. It is known that thiamine levels can vary with the type of laboratory sample used: plasma levels are indicative of short-term deficit and are not a reliable predictor of whole body thiamine stores.<sup>[10]</sup> Liquid chromatography-tandem mass spectrometry analysis of thiamine diphosphate is the most sensitive, specific and precise way to assess body stores of thiamine and is used as gold standard assay, which was also used in these cases.

Severe thiamine deficiency should always be considered in the differential diagnosis of patients presenting with shock and especially those with lactate acidosis of unknown origin, but it is often overlooked. Shoshin beriberi can also present as cardiogenic shock due to severe biventricular failure and STEMI/NSTEMI ACS which makes the diagnosis even more difficult.<sup>[14,15]</sup> Creatine kinase-MB and troponin levels can be increased and there is profound lactate acidosis because of the activation of anaerobic glucose metabolism (*figure 1*).<sup>[10,14,16]</sup>

## Conclusion

Shoshin beriberi should be considered as a causative factor in patients at risk for malnutrition presenting with severe combined cardiogenic and distributive shock and lactic acidosis. Supplementing thiamine has no known severe side effects and can bring about rapid haemodynamic stabilisation

in these severely ill individuals. All clinicians should consider administering thiamine without delay to patients at risk for thiamine deficiency who present in shock. It could even bear consideration to pre-emptively supplement thiamine to all patients admitted to ICU with an expected stay of >48 hours, as is standard of care in our centre.

## Disclosure

All authors declare no conflict of interest. No funding or financial support was received.

## References

- Martel J, Franklin D. Vitamin, B1 (Thiamine). [online] Ncbi.nlm.nih.gov. Available at: <https://www.ncbi.nlm.nih.gov/books/NBK482360/> [Accessed 20 August 2018].
- Collie J, Greaves R, Jones O, et al. Vitamin B1 in critically ill patients: needs and challenges. *Clin Chem Lab Med*. 2017;55:1652-68.
- Lei Y, Zheng M, Huang W, Zhang J, Lu Y. Wet beriberi with multiple organ failure remarkably reversed by thiamine administration. *Medicine*. 2018;97:e0010.
- Suter P, Vetter W. Diuretics and Vitamin B; Are Diuretics a Risk Factor for Thiamine Malnutrition?. *Nutr Rev*. 2009;58:319-23.
- DiNicolantonio J, Liu J, O'Keefe J. Thiamine and Cardiovascular Disease: A Literature Review. *Prog Cardiovasc Dis*. 2018;61:27-32.
- Dabar G, Harmouche C, Habr B, Riachi M, Jaber B. Shoshin Beriberi in Critically-Ill patients: case series. *Nut J*. 2015; doi: 10.1186/s12937-015-0039-7.
- Nguyen-Khoa D, Busschots G, Vallee P, et al. Beriberi (Thiamine Deficiency): Practice Essentials, Pathophysiology, Etiology [Internet]. *Emedicine.medscape.com*. 2018 [cited 15 September 2018]. Available from: <https://emedicine.medscape.com/article/116930-overview#a4>
- Lonsdale D. A Review of the Biochemistry, Metabolism and Clinical Benefits of Thiamin(e) and Its Derivatives. *Evid Based Complement Alternat Med*. 2006;3:49-59.
- van Snippenburg W, Reijnders MGJ, Hoffhuis JGM, de Vos R, Kamphuis S, Spronk PE. Thiamine levels during Intensive Insulin Therapy in critically ill patients. *Intens Care Med*. 2017;32:559-64.
- Donnino M, Andersen L, Chase M, et al. Randomized, Double-Blind, Placebo-Controlled Trial of Thiamine as a Metabolic Resuscitator in Septic Shock. *Crit Care Med*. 2016;44:360-7.
- Hens J, Prins J, Wielders J, Bartelink A. Fulminante lactatacidose en hyperfosfatemie bij een alcoholicus met een vitamine B1-deficiëntie (beriberi). *Ned Tijdschr Klin Chem*. 2000;25:365-9.
- Chisolm-Straker M, Cherkas D. Altered and Unstable: Wet Beriberi, a Clinical Review. *J Emerg Med*. 2013;45:341-4.
- Shah A, Patel S, Kothari S, Denk J. Beriberi Induced Cardiomyopathy Requiring Salvage Venoarterial Extracorporeal Membrane Oxygenation. *Case Rep Crit Care*. 2016;2016:1-5.
- TDP - Clinical: Thiamine (Vitamin B1), Whole Blood [Internet]. *Mayomedicallaboratories.com*. 2018 [cited 24 May 2018]. Available from: <https://www.mayomedicallaboratories.com/test-catalog/Clinical+and+Interpretive/42356>
- Kim J, Park S, Kim J, Kim S, Kang W, Kim S. A case of shoshin beriberi presenting as cardiogenic shock with diffuse ST-segment elevation, which dramatically improved after a single dose of thiamine : online article - case report. *Cardiovasc J Africa*. 2014;25:e1-e5.
- Loma-Osorio P, Peñafiel P, Doltra A, Sionis A, Bosch X. Shoshin Beriberi Mimicking a High-risk Non-ST-Segment Elevation Acute Coronary Syndrome with Cardiogenic Shock: When the Arteries are Not Guilty. *J Emerg Med*. 2011;41:e73-e77.