

## CASE REPORT

# Sepsis and bleeding in an obstetric patient who is a Jehovah's Witness

A case report with a brief review of the literature of severe septic shock during pregnancy

V.C. van Dam<sup>1,2</sup>, B.L. ten Tusscher<sup>1</sup>, A.R.J. Girbes<sup>1</sup>

<sup>1</sup>Department of Intensive Care Medicine, VU University Medical Center Amsterdam, The Netherlands

<sup>2</sup>Current address: Department of Intensive Care Medicine, Westfriesgasthuis Hoorn, The Netherlands

## Correspondence

V.C. van Dam – e-mail: veerlevandam@hotmail.com

**Keywords** - Sepsis, obstetric patient, Jehovah's Witness

## Abstract

Sepsis in pregnancy is an important cause of maternal deaths worldwide with the vast majority of these deaths occurring in low-income countries. In developed countries, septic shock in obstetric patients is relatively rare and not often a reason for ICU admission; eclampsia, preeclampsia and major obstetric haemorrhage are far more common reasons for ICU admission during and after pregnancy.

Due to an altered physiological status in pregnancy, early recognition and treatment of obstetric sepsis can be complicated and different from non-obstetric sepsis. Early recognition and prompt therapy is however, crucial to reduce maternal and foetal morbidity and mortality. The main goal in treating septic shock in pregnancy is to effectively resuscitate the mother as this usually adequately resuscitates the foetus. Early focused empiric antibiotic treatment should be initiated. Sepsis in obstetric patients is primarily the result of pelvic infections such as intra-amniotic infections, endometritis, septic abortions, or urinary tract infections.

We discuss a case of septic shock in an obstetric patient, highlighting the treatment of sepsis in pregnancy with an emphasis on changed physiology. In addition, we will briefly address the consequences of a patient refusing blood products in this context, as our patient did being a practising Jehovah's Witness.

## Introduction

Nowadays, maternal sepsis accounts for only a small proportion of maternal deaths in high-income countries. In western countries, reported incidences of severe maternal morbidity as a result of sepsis vary from 0.1 to 0.6 per 1000 deliveries.<sup>1</sup> Although maternal sepsis is relatively uncommon, thorough knowledge of the development of sepsis and septic shock and especially the altered physiology in pregnancy are essential in treating the obstetric patient. We discuss a complex case of septic shock in an obstetric patient in the context of the

changed physiology. In addition, we will briefly discuss the consequences of refusing blood products in pregnant Jehovah's Witnesses and the risk of maternal death.

## Case history

A 27-year-old gravida 3 para 0 was presented at the outpatient clinic at 20 weeks of gestation. Her medical history included two missed abortions for which she underwent curettage and intra-uterine adhesiolysis. She was a practising Jehovah's Witness who had signed an advanced directive declining blood transfusion in the recent past and her partner confirmed her wishes.

At 20 weeks of gestational age, routine abdominal ultrasound was performed and showed no structural abnormalities. However, a transvaginal ultrasound, which was performed within the context of scientific research, revealed shortening of the cervix length and an open ostium internum. Speculum examination followed, and showed protrusion of the amniotic membranes into the cervical channel.

The patient was admitted because of the risk of premature labour. On admission she felt well, but mentioned that she had had discoloured vaginal discharge for 2 days. Laboratory results showed a concentration of C-reactive protein of 30 mg/L with a leukocyte count of  $10 \times 10^9/L$ . Although the patient's symptoms were minimal, an infection could not be excluded and she was started on empiric intravenous amoxicillin-clavulanic acid after blood cultures had been taken. In addition, indometacine was prescribed in an attempt to delay delivery.

The following day, she was referred to our university hospital for possible tertiary cerclage. Cerclage was not performed immediately because of suspicion of infection and the risk of rupture of the membranes. On day 2 of admission, the patient's temperature went up to 40 degrees Celsius and she complained of painful contractions. Rapidly progressive hypotension and tachycardia developed and fluid resuscitation was initiated. An intra-amniotic infection with septic shock was suspected and it

was decided to terminate the pregnancy. An amniocentesis was performed, and malodorous amniotic fluid was sent for culture. Our patient received oxytocine and after 5 hours she gave birth to a dead male foetus of 473 gram. The delivery was complicated by retention of the placenta in spite of active management of the third stage of labour for which manual removal of the placenta was performed. Estimated total blood loss was 1500 ml. During the procedure the patient was haemodynamically highly unstable and needed continuous fluid resuscitation and vasopressors. In view of her confirmed Jehovah Witness conviction, blood transfusion was not an option.

After removal of the placenta, the patient was transferred to the intensive care unit where she deteriorated towards profound septic shock, multi organ failure, including acute respiratory distress syndrome (ARDS) and renal failure. Laboratory results suggested disseminated intravascular coagulation. Her haemoglobin levels dropped to 2.9 mmol/L and her platelet count dropped as low as  $13 \times 10^9/L$ . There were no laboratory signs of haemolysis. She was treated with ceftriaxone and a single dose of gentamycin. In addition to vasopressors, she was given hydrocortisone therapy at a dose of 100 mg TID i.v. Chest X-ray showed bilateral opacities compatible with ARDS. Transoesophageal echocardiography demonstrated a relatively hypovolaemic left ventricle, slight diffuse myocardial depression, but no obvious signs of cardiomyopathy. Prone position ventilation was initiated because of refractory hypoxaemia due to ARDS.

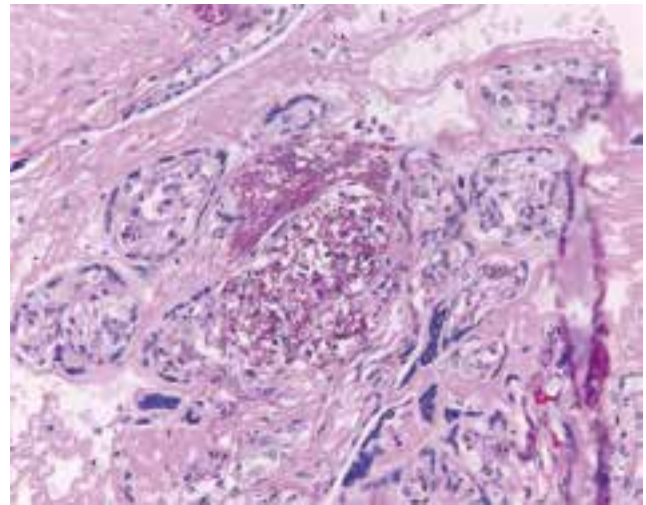
Shortly after admission to the ICU, blood cultures yielded gram-negative rods and the following day *Escherichia coli* was identified, which was also isolated from cultures of the foetal nares and external auditory canal of the foetus. The isolated *E.coli* was resistant to amoxicillin-clavulanic acid, but susceptible to cephalosporines. Histopathological examination of the placenta revealed invasion of neutrophils and bacilli into the chorionic villi (figure 1 and 2).

On the sixth day of admission, white blood cell count peaked at  $106 \times 10^9/L$ . Our patient ultimately responded to treatment and there were no haemorrhagic complications. Antibiotic treatment was administered for 10 days. Multiple organ dysfunction resolved over the following weeks. Management of the patient also included supplemental erythropoietin therapy and iron. She was on mechanical ventilation for 20 days and needed renal replacement therapy until discharge from the ICU at day 26. Renal function recovered slowly during the following weeks and after 6 weeks she was able to come off dialysis.

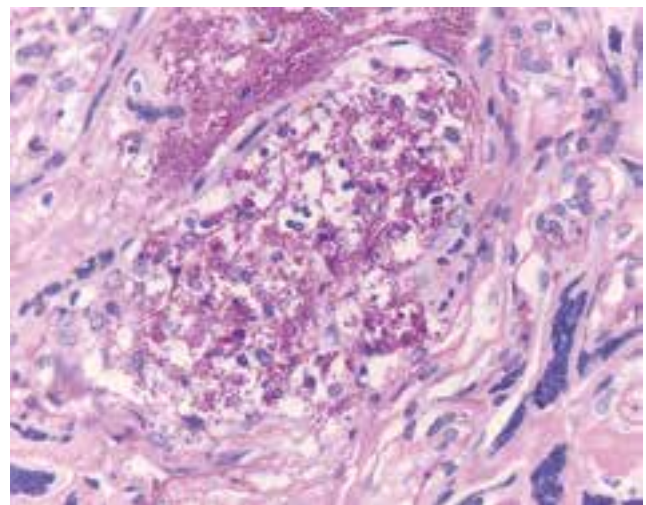
## Discussion

Severe maternal morbidity complicates at least 0.71% of all pregnancies in the Netherlands. The LEMMonN study, a Nationwide Enquiry into ethnic determinants of Severe Maternal Morbidity in the Netherlands, reported an incidence of admission to the ICU of 2.4 per 1000 deliveries between 2004

**Figure 1.** Chorionic villi heavily infiltrated by numerous neutrophils



**Figure 2.** Chorionic villus showing bacilli and neutrophils



and 2006.<sup>2</sup> The most common reasons for ICU admission are preeclampsia, eclampsia, and major obstetric haemorrhage.<sup>3</sup> In developed countries, septic shock in obstetric patients is rare. Kramer et al. found an incidence of severe sepsis of 0.2 per 1000 deliveries.<sup>4</sup> Sepsis in obstetric patients is primarily the result of pelvic infections due to intra-amniotic infections, endometritis, wound infections, septic abortions, or urinary tract infections.

Intra-amniotic infection (IAI) refers to infection of the amniotic fluid, membranes, placenta and/or decidua. Studies indicate that IAI complicates between 0.5% and 10% of all pregnancies.<sup>5,6</sup> Any factor that increases the risk of prolonged exposure of the foetal membranes to ascending microbes from the vagina will increase the risk of IAI (e.g. preterm delivery and number of vaginal examinations). The pathogens most

frequently isolated from the amniotic fluid are *Gardnerella vaginalis*, *Ureaplasma urealyticum*, *Bacteroides bivius*, Streptococci and *Escherichia coli*. Approximately 5 to 10 % of women with IAI will develop bacteraemia, but only a small number of these patients develop septic shock. In those who do develop sepsis, studies have shown aerobic gram-negative rods to be the principal etiologic agents, followed by gram-positive bacteria and mixed or fungal infections.<sup>7</sup>

Several complex physiologic adaptations occur during pregnancy, which can mask the initial signs of sepsis and make these patients susceptible to rapid deterioration. These physiological changes must be taken into account when treating the infectious obstetric patient.<sup>8</sup> First, in pregnant patients, blood pressure is often decreased as a result of a decrease in vascular resistance. Arterial pressure during pregnancy is predominantly maintained by increased cardiac output due to an increase in stroke volume, particularly in the first two trimesters. As a result, maternal cardiovascular functional residual capacity is limited and sepsis-induced myocardial contractile dysfunction can rapidly lead to haemodynamic collapse.<sup>9</sup>

Progesterone, produced by the placenta, has a respiratory stimulant effect and leads to an increase in tidal volume and a generally unchanged respiratory rate. Functional residual capacity is decreased by 25%, and oxygen consumption increases as a result of increased metabolic needs of the mother and foetus. Arterial blood gas analysis typically shows respiratory alkalosis. Although this adaptation is beneficial in normal pregnancy, in the setting of sepsis and/or respiratory failure, these changes predispose the patient to a rapid decline in oxygenation and decreased ability to compensate or buffer metabolic acidosis.<sup>8,10</sup>

During pregnancy the plasma volume increases up to 10-15%, albumin and protein concentrations decrease, resulting in lower osmotic pressure, predisposing for an accumulation of interstitial fluid. Consequently, pregnant patients are more susceptible to pulmonary oedema.

The increased plasma volume is greater than the increase in haemoglobin mass and erythrocyte volume. This is responsible for a modest fall in the haemoglobin level, called dilutional (physiological) anaemia of pregnancy.

The early recognition of the condition and subsequent prompt treatment is crucial to reducing maternal and foetal morbidity and mortality in women with suspected sepsis. The overall goal in the management of pregnancy that is complicated by septic shock is to immediately resuscitate the mother. Resuscitation of the mother will usually adequately resuscitate the foetus. Delivery in the setting of maternal instability increases maternal and foetal mortality rates.<sup>11</sup> The only obvious exception is if the intra-uterine environment is the source of infection, as in our case, in which prompt delivery may be life-saving.

A pregnant hypotensive patient is best placed in a left lateral tilt to prevent compression of the inferior vena cava by the gravid uterus from 20 weeks pregnancy on. As in non-pregnant patients, initial resuscitation consists of administering crystalloids or colloids to restore and maintain tissue perfusion. Early goal directed therapy with goals as described by the Surviving Sepsis Campaign are already a subject of discussion in the general population and may not be directly applicable to pregnant patients with shock and sepsis – as normal values during pregnancy differ from non-pregnant patients. No studies have specifically evaluated the use of CVP measurements in obstetrical patients with sepsis. Invasive monitoring with a pulmonary artery catheter has been studied in obstetric patients,<sup>12-14</sup> but its use in gravid and non-gravid septic patients remains undetermined.

There is no contraindication for the use of inotropes and/or vasopressors in gravid patients and inotropic therapy may be necessary to optimize haemodynamic status. The vasopressor of choice for maternal hypotension is not completely clear. Few studies have been performed in humans, but these do not provide conclusive data, however norepinephrine and dopamine can be used to increase maternal blood pressure but both can decrease uterine blood flow due to the vasoconstriction of uterine vascular beds.<sup>15,11</sup> Frequent clinical assessment of organ perfusion, and early foetal monitoring (which can reflect derangements of the mother's condition) are essential.

The identification and prompt eradication of the source of infection is of extreme importance in treating sepsis both in pregnant and non-pregnant patients. A septic abortion (although rare in the Netherlands) should be curettaged promptly and wound infections opened and debrided. Necrotizing fasciitis can be rapidly fatal and must be treated aggressively. Surgical or imaging-guided percutaneous or transvaginal drainage of the infectious focus is essential in patients with severe intra-abdominal or pelvic infections. In cases of an intra-amniotic infection, delivery should be accomplished as soon as possible, regardless of gestational age. Intravenous broad-spectrum antibiotics should be administered, starting within 1 hour of the diagnosis of severe sepsis or septic shock, preferably after blood cultures have been obtained. The choice of antibiotic is based on the suspected infection site and likely causative micro-organism. Empirical antibiotic selection should address the safety of the drug to the foetus, especially during the first trimester, when major organogenesis takes place.

The prognosis of recovery from septic shock in the gravid patient seems favourable, and the risk of death is much lower when compared with that of a non-gravid population. This has been attributed to a lack of associated underlying co-morbid conditions, younger age group, and a focused site of potential infection such as the pelvis (that may be more amenable to medical and

surgical intervention).<sup>9</sup> Still, sepsis is a life-threatening condition for women during pregnancy, childbirth, and puerperium.<sup>4</sup> Evidence-based guidelines may further reduce the overall risk of mortality and morbidity from maternal sepsis. Although approaches like the Surviving Sepsis Campaign are unproven in the obstetric population, the basic principles of prompt resuscitation, antibiotic treatment and source control are likely to be applicable to all patients with sepsis.

In our case, treatment was complicated because the patient was a practising Jehovah's Witness and refused blood products. In the United Kingdom, the 2003-2005 Confidential Enquiry into Maternal and Child Health reported haemorrhage to be the second leading cause of direct maternal death and included 14 women who had declined blood transfusion.<sup>16</sup> Recently, a retrospective study in the Netherlands by Van Wolfswinkel et al., found that women who are Jehovah's Witnesses, are at a six times increased risk for maternal death and at a 130 times increased risk for maternal death because of major obstetric haemorrhage, compared to the general Dutch population.<sup>17</sup> Oxygen transport can be impaired by low haemoglobin concentrations, especially in cases of sepsis. However, optimization of cardiac output and oxygen tension can modulate this effect.<sup>18</sup> Monitoring continuous cardiac output can be useful for assessing tissue oxygen delivery and to guide treatment in post-partum anaemia in Jehovah's Witnesses – bearing in mind the described altered physical changes in pregnancy.<sup>19</sup>

### Conclusion

We have described a complex case of an *E.coli* sepsis due to an intra-uterine infection complicated by ARDS, acute renal failure, severe anaemia and disseminated intravascular

coagulation in a patient who was a Jehovah's Witness. Maternal sepsis accounts for a small proportion of maternal deaths in high-income countries. In spite of lower mortality rates compared to non-obstetric patients with sepsis, this condition can constitute a life-threatening situation for young expectant women and needs prompt and effective treatment. Sepsis in these women can be difficult to identify because of the distinct physiological changes in pregnancy. Knowledge of these changes is essential in order to properly interpret the hemodynamic data and to identify the risk of rapid deterioration in septic obstetric patients. Further, in practising Jehovah's Witnesses, haemorrhage should be treated sufficiently, which may include a rapid decision to proceed to hysterectomy when indicated.

### References

1. Van Dillen J, Zwart J, Schutte J, van Roosmalen J. Maternal sepsis: epidemiology, etiology and outcome. *Curr Opin Infect Dis* 2010;23:249-254
2. Zwart JJ, Richters JM, de Vries JIP, Bloemenkamp KWM, van Roosmalen J. Severe maternal morbidity during pregnancy, delivery and puerperium in the Netherlands: a nationwide population-based study of 371 000 pregnancies. *British Journal of Obstetrics and Gynecology* 2008;115:842-850
3. Keizer JL, Zwart JJ, Meerman RH, Harinck BIJ, Feuth HDM, van Roosmalen J. Obstetric intensive care admissions: A 12-year review in a tertiary care centre. *Eur J Obstet Gynecol and Repr Biol* 2006;128:152-156
4. Kramer HMC, Schutte JM, Zwart JJ, Schuitemaker NEW, Steegers EAP, van Roosmalen J. Maternal mortality and severe morbidity from sepsis in the Netherlands. *Acta Obstetrica et Gynecologica* 2009;88:647-653
5. Soper D, Mayhall C, Dalton H. Risk factors for intraamniotic infection: A prospective epidemiologic study. *Am J Obstet Gynecol* 1989;161:562-568
6. Soper D, Mayhall C, Frogatt J. Characterization and control of intraamniotic infection in an urban teaching hospital. *Am J Obstet Gynecol* 1996;175:304-310
7. Fahey OF. Clinical management of intra-amniotic infection and chorioamnionitis: A review of literature. *J Midwifery Womens Health* 2008;53:227-235
8. Fujitani S, Baldisseri MR. Hemodynamic assessment in a pregnant and peripartum patient. *Crit Care Med* 2005;33:No.10 (Suppl.)
9. Fernandez-Perez ER, Salman S, Pendem S, Farmer JCh. Sepsis during pregnancy. *Crit Care Med* 2005;33:No.10 (Suppl.)
10. Cole DE, Taylor TL, McCullough DM, Shoff CT, Derdak SD. Acute respiratory distress syndrome in pregnancy. *Crit Care Med* 2005;33:No. 10 (Suppl.)
11. Sheffield JS. Sepsis and septic shock in pregnancy. *Crit Care Clin* 2004;20:651-660
12. Belfort MA, Mares A, Saade GR et al. Rapid echocardiographic assessment of left and right heart hemodynamics in critically ill obstetric patients. *Am J Obstet Gynecol* 1994;171:884-892
13. Gilbert WM, Towner DR, Field NT et al. The safety and utility of pulmonary artery catheterisation in severe preeclampsia and eclampsia. *Am J Obstet Gynecol* 2000;182:1397-1403
14. Wallenburg HC. Invasive hemodynamic monitoring in pregnancy. *Eur J Obstet Gynecol Reprod Biol* 1991;42:S45-S51 (Suppl.)
15. Guinn DA, Abel DE, Tomlinson MW. Early Goal Directed Therapy for Sepsis During Pregnancy. *Obstetrics and Gynaecology Clinics of North America* 2007;34:459-479
16. Lewis G. The Confidential Enquiry into Maternal and Child Health (CEMACH). Saving mothers' lives: reviewing maternal deaths to make motherhood safer-2003-2005. The seventh report on confidential enquiries into maternal deaths in the United Kingdom, London: CEMACH; 2007.
17. Van Wolfswinkel ME, Zwart JJ, Schutte JM, Duvekot JJ, Pel M, van Roosmalen J. Maternal mortality and serious maternal morbidity in Jehovah's witnesses in the Netherlands. *BJOG* 2009;116:1103-1110
18. Rasanayagam SR, Cooper GM. Two cases of severe postpartum anemia in Jehovah's witnesses. *Int J Obstet Anesth* 1996;5:202-5.
19. Piraccini E, Corso RM, Agnoletti V, Terzitta M, Valtancoli E, Gambale G. Cardiac output and fluid replacement in a Jehovah's Witness with severe postpartum hemorrhage. *Int J Obstet Anesth*. 2010 Oct;19(4):462-3

