

CASE REPORT

Paracetamol-induced hypotension on the intensive care unit

K.R. Charaghvandi¹, P.D.J. Bollen², M. Duisenberg-van Essenberg², A.M.F. Rutten¹

¹Department of Intensive Care Medicine, St. Elisabeth Hospital, Tilburg, the Netherlands (currently working at Department of Radiotherapy, University Medical Center Utrecht, Utrecht, the Netherlands), ²Hospital Pharmacy Midden-Brabant, St. Elisabeth Hospital and TweeSteden Hospital, Tilburg, the Netherlands

Correspondence

K.R. Charaghvandi – email: R.Charaghvandi@umcutrecht.nl

Keywords – paracetamol, ICU, hypotension, case report

Abstract

Paracetamol has acquired a well-established role for pain relief and fever management throughout the whole world. It is a well-accepted drug in the clinical setting given its predictable side effect range. In the following case report, we present hypotension as an unfamiliar side effect, found in a neurologically impaired patient in our intensive care unit. In addition, an outline on the pharmacology and pharmacodynamic features of paracetamol will be given.

Introduction

Paracetamol is one of the most commonly used analgesics worldwide given its limited report of side effects in therapeutic dosage.^{1,2} Due to its perceived safety, paracetamol is available as a non-prescription drug and is also frequently used in clinical settings.^{1,2} In the following case report, we outline hypotension as an underestimated side effect of paracetamol use in the critically ill.

Case history

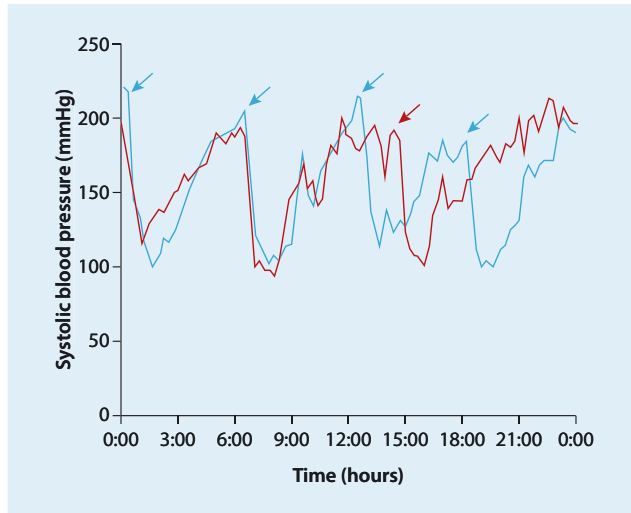
A 77-year-old woman presented to the emergency department with acute onset of severe headache, vomiting and confusion. Her medical history included hypertension, osteoporosis and heavy smoking. Her medication included a non-steroidal anti-inflammatory drug (NSAID), a proton pump inhibitor and a bisphosphonate tablet. The patient reported no allergies to any known medication.

At presentation the patient had a maximal Glasgow Coma Scale (GCS) score of 15 and a tardy responsiveness without any focal neurological abnormalities. However, the patient was transferred to the intensive care unit (ICU) due to a massive subarachnoid haemorrhage and an incipient hydrocephalus. A positive fluid balance was maintained and nimodipine and analgesic treatment with paracetamol 1 gram, four times a day through a gastric

feeding tube, was initiated. A coiling procedure was performed on an aneurysm of the anterior communicating artery. Following the procedure, the neurological status of the patient deteriorated due to a worsening of the hydrocephalus. An external ventricular drain was placed but only temporary recovery was observed. The hospitalisation was further complicated by a bacterial meningitis, a delirium episode and an exacerbation of a not previously diagnosed lung emphysema, which required mechanical ventilation. In addition, neurological impairment due to focal epilepsy and vasospasm was suspected and treated.

By day 29 the patient's neurological response was evaluated as E3M5Vt. During the morning round, an association was observed between paracetamol administration and episodes of hypotension with the systolic blood pressure as low as 94 mmHg (*figure 1*). Pain assessment was not reliable in the neurologically impaired patient. The hypotension episode was not likely to have been induced by other concomitantly administered medication. The renal function of the patient was not impaired and no alteration in creatinine levels and creatinine clearance was seen. The planned paracetamol dose was subsequently omitted. No blood pressure alterations were observed, although fever developed temporarily. After a couple of hours, a decreased dose of paracetamol was administered and a systolic blood pressure decline to 101 mmHg was reported. The paracetamol was discontinued and no further cyclical episodes of hypotension or fever occurred. In retrospect, no associations were found between the hypotension episodes and alterations in neurological status and no haemodynamic interventions were required. During the subsequent hospitalisation period, the patient had a fluctuating GCS with spontaneous eye opening, an alternating motor response ranging from no response to toe or tongue movement on request and no verbal response. On day 50, the patient was discharged to a nursing home for further revalidation. The patient died two months later.

Figure 1. The blue line illustrates 24-hour blood pressure variation on the day before paracetamol discontinuation. Blue arrows at 00:00 – 06:00 – 12:00 – 18:00 indicate the time of paracetamol administration. The red line illustrates 24-hour blood pressure variation on the day of paracetamol discontinuation. Paracetamol is administered at 00:00 and 06:00. The planned paracetamol dose is not administered at 12:00. The red arrow indicates the paracetamol rechallenge test at 14:00.



Discussion

Paracetamol use has previously been reported to be associated with hypotension on the ICU, consistent with the observations in our patient.³⁻¹⁰ Whereas in our case the drug was administered orally, the great majority of the studies concern intravenous paracetamol administration. Estimating an incidence rate of paracetamol-induced hypotension from the medical literature is difficult given the heterogeneity in study population together with differences in drug dosage, route of drug administration or the definition of a hypotensive episode. The largest study, by Mrozek *et al.*, observed a significant associated decrease in blood pressure in 17 (13%) of the 127 critically ill ICU patients, corresponding to 1.33% of the 1507 intravenous paracetamol administrations.⁶ This decrease was defined as a reduction of more than 20% in systolic blood pressure within three hours after paracetamol administration. In ten (59%) of the 17 patients with blood pressure alterations, an intervention for haemodynamic recovery was needed. Other studies, with smaller study populations, observed a paracetamol-associated blood pressure decline in 22-59% of the ICU patients or report this in terms of 33-45% of all drug administrations.⁷⁻¹⁰ These figures differ from the information in the summary of product characteristics of intravenous paracetamol, where hypotension is considered to occur with a likelihood of 0.1 to 1%.¹¹

Paracetamol is an acetanilide derivate used on the ICU due to its analgesic and antipyretic properties.¹ The mechanism of action for its analgesic effects is suggested to be multifactorial

and has not yet been elucidated. In contrast to other cyclo-oxygenase (COX) inhibitors, which act both centrally and peripherally, a common hypothesis for the analgesic and antipyretic properties postulates that paracetamol acts primarily centrally as an indirect COX inhibitor. However, its anti-inflammatory activity is very weak.¹²

Another hypothesis on its analgesic effect postulates that paracetamol could indirectly attenuate nociception. Normally, activation of the hypothalamic N-methyl-D-aspartate receptor (NMDA receptor) leads to increased production of nitric oxide (NO), which amplifies neuronal activity and facilitates nociception. Paracetamol is thought to counteract this process through inhibition of nitric oxide synthase, thereby decreasing the NO production. Other explanatory mechanisms for pain relief involve metabolites of paracetamol (e.g. N-arachidonoylphenolamine (AM404)), which activate the endocannabinoid system in nociceptive pathways in the central nervous system. In addition, an analgesic effect is proposed by an indirect increase in 5-hydroxytryptamine (HT) levels and by downregulation of 5HT_{2A} receptors in descending serotonergic pathways in the spinal cord. Finally, it is suggested that endogenous opioids contribute to the antinociceptive effects of paracetamol at the spinal and supraspinal level. Furthermore, some studies state that the antipyretic effects are due to the interference of paracetamol and perhaps its metabolites in hypothalamic areas where the body temperature is regulated.¹²

An explanation for the paracetamol-induced hypotension is so far uncertain; nevertheless there are several hypotheses that link the pharmacodynamics to the physiological effect on blood pressure. In a prospective observational study by Boyle *et al.* on febrile patients in the ICU, hypotension following enteral or intravenous paracetamol administration was associated with an increase in skin blood flow.⁸ In a control group consisting of healthy, afebrile volunteers no haemodynamic changes were observed following paracetamol ingestion. These observations in febrile patients are attributed to paracetamol resetting the central thermoregulatory set-point thereby initiating the physiological mechanism for heat loss by means of cutaneous vasodilatation. If assuming that autonomic (baroreceptor) dysfunction is associated with critical illness, when a greater percentage of cardiac output is redirected to the skin, an inadequate response to blood pressure changes such as hypotension could be observed in ICU patients. Krajčová *et al.* conducted a cross-over study where critically ill patients received intravenous paracetamol versus ranitidine, a control drug that could not exert blood pressure alteration. The haemodynamic consequences were monitored by means of pulse-induced contour cardiac output (PiCCO) monitoring. Following paracetamol administration a reduction in mean arterial pressure of 5% was observed. This was associated with a decrease in both peripheral vascular resistance and

cardiac output. In addition, a slight trend towards heart rate decrease was observed. It was therefore hypothesised that the analgesic action of paracetamol reduced the sympathetic tone resulting in a negative inotropic effect, thereby decreasing the stroke volume and heart rate and thus the cardiac output.⁹ In contrast to Boyle *et al.* who observed paracetamol-associated blood pressure alterations in febrile patients, this study found no relationship between the peripheral vascular resistance and a central-peripheral temperature gradient.⁸ Hersch *et al.* state that hypotension caused by a decrease in cardiac output is not easily corrected by the critically ill, who often experience vasoplegia and are therefore unable to maintain their blood pressure by compensatory vasoconstriction.⁷ However, when postulating an effect of paracetamol on fluid balance through a COX-inhibition pathway, a possible kidney-related mechanism for the hypotension seems unlikely.¹² In case of NSAIDs inhibiting COX, the synthesis of prostaglandins is reduced. This can cause a decrease in compensatory vasodilation by prostaglandins, leading to a decrease in renal blood flow and glomerular filtration rate. This is more likely to lead to hypertension. Berg *et al.* observed that in the elderly or patients with impaired renal function, urinary prostaglandin excretion is reduced following paracetamol administration; nevertheless renal glomerular and tubular function parameters were unchanged.¹³ Only a few risk factors, such as brain injury or sepsis, are reported to be associated with the occurrence of a hypotensive episode following paracetamol administration in ICU patients.⁶ In a Dutch study on medium care and ICU patients, no risk factors, including the APACHE II score, were identified to correlate with a paracetamol-induced blood pressure decline.¹⁰ Interestingly, clinical studies in healthy or non-critically ill patients with coronary artery disease support the association between chronic paracetamol use and elevated blood pressure.²

An important issue in the discussion concerns the clinical implications of paracetamol-induced hypotension in the critically ill, a matter that has to be further investigated. An ongoing multicentre randomised placebo-controlled trial investigating the efficacy and safety of intravenous paracetamol in ICU patients with fever and infection, the HEAT trial, will hopefully provide more information on the use of this drug in the critically ill.¹⁴

When evaluating our clinical case in retrospect, no associations were found between hypotension episodes and an alternating GCS. We therefore attributed the impaired neurological status of our patient to the massive subarachnoid haemorrhage and its multiple complications. A contribution of paracetamol-induced hypotension to the neurological outcome cannot be established with certainty.

Conclusion

Whereas paracetamol is generally considered a safe analgesic and antipyretic drug, physicians should not underestimate the possible adverse effect on blood pressure in the critically ill.

REFERENCES

1. Jefferies S, Saxena M, Young P. Paracetamol in critical illness: a review. *Critical Care Resusc.* 2012;14:74-80.
2. Turtle EJ, Dear JW, Webb DJ. A systematic review of the effect of paracetamol on blood pressure in hypertensive and non – hypertensive subjects. *Br J Clin Pharmacol.* 2013;75:1396-405.
3. Brown G. Acetaminophen-induced hypotension. *Heart Lung.* 1996;25:137-40.
4. Boyle M, Hundy S, Torda TA. Paracetamol administration is associated with hypotension in the critically ill. *Aust Crit Care.* 1997;10:120-2.
5. Mackenzie L, Forrest K, Thompson F, Marsh R. Effects of acetaminophen administration to patients in intensive care. *Intensive Care Med.* 2000;26:1408.
6. Mrozek S, Constantin JM, Futier E, et al. Acetaminophen-induced hypotension in intensive care unit: a prospective study. *Ann Fr Anesth Reanim.* 2009;28:448-53.
7. Hersch M, Raveh D, Izbicki G. Effect of Intravenous Propacetamol on Blood Pressure in Febrile Critically Ill Patients. *Pharmacotherapy.* 2008;28:1205-10.
8. Boyle M, Nicholson L, O'Brien M, et al. Paracetamol induced skin blood flow and blood pressure changes in febrile intensive care patients: an observational study. *Aust Crit Care.* 2010;23:208-14.
9. Krajčová A, Matoušek V, Duška F. Mechanism of paracetamol induced hypotension in critically ill patients: A prospective observational cross-over study. *Aust Crit Care.* 2012; 26:136-41.
10. Maat de M, Tijssen TA, Brüggemann RJ, Ponsen HH. Paracetamol for intravenous use in medium and intensive care patients: pharmacokinetics and tolerance. *Eur J Clin Pharmacol.* 2010;66:713-9.
11. Product information. Paracetamol 10 mg/ml, solution for infusion. Fresenius Kabi Nederland BV. 21 October 2010.
12. Toussaint K, Yang XC, Zielinski MA, et al. What do we (not) know about how paracetamol (acetaminophen) works? *J Clin Pharm Therapeut.* 2010;25 617-38.
13. Berg KJ, Djøseland O, Gjellan A, et al. Acute effects of paracetamol on prostaglandin synthesis and renal function in normal man and in patients with renal failure. *Clin Nephrol.* 1990;34:255-62.
14. Young PJ, Saxena MK, Bellomo R, et al. The HEAT trial: a protocol for a multicentre randomized placebo controlled-trial of IV paracetamol in ICU patients with fever and infection. *Crit Care Resusc.* 2012;14:290-6.