

## CASE REPORT

# Massive rhabdomyolysis due to corticosteroids and muscle blocking agents, proven by rechallenge

V.L. Schouten, J.I. van der Spoel

Department of Intensive Care Medicine, Amsterdam UMC, Vrije Universiteit Amsterdam, Amsterdam, the Netherlands

## Correspondence

V.L. Schouten - viviane\_schouten@hotmail.com

**Keywords** - rhabdomyolysis, corticosteroids, neuromuscular blocking agents

## Abstract

Rhabdomyolysis due to high-dose steroids and non-depolarising muscle blocking agents is relatively uncommon.

We report a case of a 36-year-old man with severe respiratory failure due to hypersensitivity pneumonitis requiring mechanical ventilation. He was given high doses of parenteral steroids, neuromuscular blockade with non-depolarising agents and low tidal volume ventilation. He developed severe rhabdomyolysis with elevated creatine kinase levels (CK >50,000 U/l) and renal impairment requiring continuous venovenous haemofiltration. The aetiology for this rhabdomyolysis appears to be related to therapy with steroids in combination with muscle blocking agents and respiratory acidosis. This diagnosis was confirmed because deterioration of his pulmonary condition required reinstatement of high-dose steroid therapy, again leading to rhabdomyolysis. Patients treated with steroids and neuromuscular blocking agents should be regularly monitored for rhabdomyolysis. Physicians need to be aware of this relatively rare complication.

## Introduction

In the last decades several case reports have appeared about acute myopathy complicating mechanical ventilation for severe asthma, which is more common in children.<sup>[1-5]</sup> The exact aetiology is not entirely clear but the reports claim that the myopathy is caused by a combination of high-dose steroids, neuromuscular blocking drugs and possibly an accompanying respiratory acidosis.

In the last ten years lung protective ventilation using low tidal volumes, neuromuscular blocking agents and the prone position has become increasingly important in ARDS patients. However, in ARDS trials rhabdomyolysis is never mentioned.<sup>[6,7]</sup>

Rhabdomyolysis is a condition in which adenosine triphosphate depletion plays a key role causing skeletal muscle to break down rapidly with the release of intracellular muscle constituents such as creatine kinase, myoglobin and various electrolytes. Some of the muscle breakdown products, such as heme pigment

casts and free chelatable iron, are harmful to the kidneys and can cause renal failure. Rhabdomyolysis can be seen in different grades of severity: from asymptomatic elevated serum muscle enzymes to rare life-threatening electrolyte imbalances and acute kidney injury.

The trigger for muscle cell death can be divided into traumatic (for example crush syndrome, prolonged immobilisation) or non-traumatic causes. A non-traumatic cause for rhabdomyolysis is often clear from the recent medical history or medication but in some cases it is not immediately evident. We will describe a 36-year-old man who was treated for hypersensitivity pneumonitis which was complicated by severe rhabdomyolysis causing renal failure requiring continuous venovenous haemofiltration.

## Case report

A 36-year-old man presented to the emergency department in another hospital because of rapidly progressive shortness of breath. He had no significant previous medical history except for smoking marijuana with a vaporiser a week before hospital admission. Recently, he had helped a friend to hay his land.

On presentation he had fever and rhonchi over all lung fields. Bilateral infiltrates were seen on the chest X-ray and he was admitted to the general ward where antibiotic treatment with ceftriaxone and ciprofloxacin was started for community-acquired pneumonia, following the local guideline. During a bronchoalveolar lavage his respiratory status worsened making intubation and mechanical ventilation necessary. The next day he was transferred to our ICU for additional diagnostic procedures and possible extra-corporal life support. CT scan showed diffuse pulmonary nodules and a tree-in-bud sign. The cultures of the bronchoalveolar lavage were negative, including yeast and fungi. Auramine staining and molecular analysis for viral and atypical organisms was also negative. Serology for HIV, CMV, EBV, leptospirosis and hantavirus was negative as well.

Autoimmune diseases were excluded by performing an ANA which was negative, as well as anti-ENA, rheumatoid factor, anti-CCP, ANCA and anti-ds DNA.

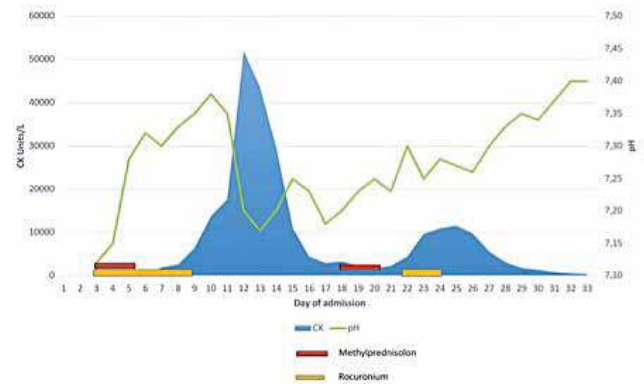
We considered diffuse panbronchiolitis caused by exposure to an allergenic substance (marihuana or hay) or hypersensitivity pneumonitis as the most probable causes and he was given a three-day course of methylprednisolone 1000 mg/day. Because of his poor respiratory status with acute respiratory distress syndrome, he received low tidal volume ventilation and rocuronium, a non-depolarising neuromuscular blocking agent in order to achieve lung protective ventilation; respiratory acidosis with a pH of 7.15 and PCO<sub>2</sub> of 14 kPa was accepted. With worsening oxygenation and trying to mobilise sputum, the patient was also ventilated in the prone position.

On the fifth day after the start of the methylprednisolone, after receiving rocuronium for 7 days, his creatine kinase levels, which we measure daily, started to rise to peak at 52,000 IU/l on day 12. At first he was sedated with propofol (<4 mg/kg/h), but after the CK started to rise this was switched to midazolam. He developed anuria with refractory hyperkalaemia and he was started on continuous venovenous haemofiltration on day 11. To rule out other causes for his rhabdomyolysis, such as myositis, a biopsy of the left quadriceps muscle was performed which showed minor aspecific abnormalities including regeneration, degeneration and focal necrosis. We excluded other causes such as leptospirosis by negative PCR and propofol infusion syndrome because he did not receive high doses of propofol, did not have a metabolic acidosis or elevated lactate levels nor did he have high blood triglycerides. So his renal failure was attributed to nephropathy caused by muscle breakdown products as heme pigment casts and free chelatable iron.

A week after treatment with methylprednisolone, we saw a slight improvement of his respiratory condition so we tried to ventilate him in support mode. However, his work of breathing and respiratory drive were too high so we had to reinstitute high-dose sedation with midazolam and ventilate him in control mode again. On day 12 we performed a new bronchoscopy which showed no abnormalities and infectious causes were again excluded. A CT scan showed, in addition to the centrilobular nodules, new areas with ground glass in the upper lobes, middle lobe and lingula. We concluded that hypersensitivity pneumonitis was still the most likely diagnosis and azithromycin was started because of presumed positive immunomodulatory effects, in addition to his maintenance therapy with prednisone 60 mg per day.<sup>[8]</sup>

His respiratory condition slowly deteriorated in the following week, which was not caused by secondary infection because he did not develop a fever, there was no rise in the inflammation parameters and no purulent secretions. The slow decline in respiratory dynamics and worsening respiratory acidosis required reinstitution of high-dose steroid therapy even though we attributed the episode of rhabdomyolysis with renal failure to

the high-dose parenteral steroids and neuromuscular blocking agents used previously. We started a second three-day course of methylprednisolone with additional cyclophosphamide on day 21 and on day 22 continuous rocuronium was also reinstated because of severe patient-ventilator dyssynchrony. The patient was still on continuous haemofiltration during this rechallenge and unfortunately but not unexpectedly again had a significant elevation of CK levels as shown in *figure 1*.



**Figure 1.** The course of CK and various influencing factors

The week after this rechallenge the patient slowly improved and on day 33 he could be extubated successfully. His kidney function was recovering and he was taken off continuous venovenous haemofiltration after five weeks. He had a significant ICU-acquired weakness or ‘necrotising myopathy of intensive care’ and stayed in intensive and medium care for a total of six weeks, after which he could be discharged to a rehabilitation centre where he stayed for another six weeks.

## Discussion

A few case reports have appeared dealing with acute myopathy complicating ventilation for acute asthma exacerbations.<sup>[1-4]</sup> Most of this literature is about children. The occurrence of myopathy or even rhabdomyolysis in adults is rare, especially with subsequent development of renal impairment and the necessity to use renal replacement therapy.

Our case report establishes the causal relationship between rhabdomyolysis and therapy with high-dose parenteral steroids and muscle-relaxant agents by doing a - medically necessary - rechallenge.

In his case report and review of previous cases, Griffin<sup>[5]</sup> states that it is the combination of steroids and neuromuscular blocking agents which causes severe acute myopathy. The authors claim that the severe myopathy is not only caused by high-dose steroids because patients receiving only steroids may experience subacute instead of acute muscle weakness. Furthermore these patients did not develop rhabdomyolysis with high CK levels let alone renal failure.<sup>[9]</sup> In 2006, Steinberg

et al. found an association between corticosteroids and neuromyopathy but this study was underpowered to assess any difference in incidence of neuromyopathy of less than 25% and they did not mention patients developing rhabdomyolysis.<sup>[10]</sup>

It is also unlikely that the neuromuscular blocking agents alone caused this severe rhabdomyolysis. Although neuromuscular blocking agents are known to cause ICU-acquired weakness or muscle atrophy, there is little literature about the severity of myopathy or rhabdomyolysis. In 2010, Papazian showed that there was no significant difference in ICU-acquired paresis in patients treated with cisatracurium for 48 hours in comparison with placebo.<sup>[7]</sup> There are a few patients treated with neuromuscular blocking agents who developed severe myopathy but most of these patients had concurrent causes such as septic shock, multi-organ failure or prolonged hypoxaemia; some of them also received steroids.<sup>[11,12]</sup> Kaplan et al.<sup>[13]</sup> describe that pancuronium and vecuronium have a very similar steroidal structure that may act in an additive manner with steroids to cause myopathy. Rocuronium is an aminosteroid non-depolarising neuromuscular blocker with a similar structure to that of the above-mentioned neuromuscular blocking agents.

Over the last ten years, the treatment of severe respiratory insufficiency has been centred on lung protective ventilation. Lung protective ventilation is a strategy using low tidal volume ventilation to prevent alveolar overdistension. This strategy is often well tolerated although patients may develop hypercapnic respiratory acidosis requiring more sedation and neuromuscular blockade to prevent asynchrony. Sedation and neuromuscular blockade might increase the risk for myopathy but severe rhabdomyolysis is not seen.<sup>[14,15]</sup> High-dose methylprednisolone in combination with neuromuscular blockade may cause rhabdomyolysis and we established this conclusion by doing a rechallenge. A rechallenge is the ultimate proof of a causal relationship in uncontrolled studies and was not performed in previous literature concerning this subject.

Besides the causal role of high-dose steroids and neuromuscular blocking agents in causing rhabdomyolysis, the underlying respiratory acidosis might have been an extra predisposing factor for renal failure as hypercapnia has vasoactive properties that may have impaired renal blood flow by renal vasoconstriction.<sup>[16]</sup> In conclusion, in the ICU recognition of this rare occurrence and cause of rhabdomyolysis is important and we recommend routine measurements of CK in all respiratory insufficient patients treated with high-dose steroids and neuromuscular blocking agents. This might detect rhabdomyolysis at an early stage in these critically ill patients.

### Disclosures

All authors declare no conflict of interest. The patient gave written informed consent prior to writing this case report.

### References

- Goh AY, Chan PW. Case report; Acute myopathy after status asthmaticus: steroids, myorelaxants or carbon dioxide? *Respirology*. 1999;4:97-9.
- MacFarlane IA, Rosenthal FD. Severe myopathy after status asthmaticus. *Lancet*. 1977;2:615.
- Knox AJ, Mascie-Taylor BH, Muers MF. Acute hydrocortisone myopathy in severe asthma. *Thorax*. 1986; 41:411-2.
- Williams TJ, O'Hehir RE, Czarny D, Horne M, Bowes G. Acute myopathy in severe asthma treated with intravenously administered corticosteroids. *Am Rev Respir Dis*. 1988;137:460-3.
- Griffin D, Fainnan N, Coursin D, Rawsthorne L, Grossman J. Acute Myopathy during Treatment of Status Asthmaticus with Corticosteroids and Steroidal Muscle Relaxants. *Chest* 1992;102:510-4.
- Acute Respiratory Distress Syndrome Network. Ventilation with lower tidal volumes as compared with traditional tidal volumes for acute lung injury and the acute respiratory distress syndrome. *N Engl J Med*. 2000;342:1301-8.
- Papazian L, Forel JM, Gacouin A, et al: Neuromuscular blockers in early acute respiratory distress syndrome. *N Engl J Med*. 2010;363:1107-16.
- Cramer CL, Patterson A, Alchakaki A, Soubani AO. Immunomodulatory indications of azithromycin in respiratory disease: a concise review for the clinician. *Postgrad Med*. 2017;129:493-99.
- Gooch J, Suchyta M, Balhierz J, Petajan J, Clemmer T. Prolonged paralysis after treatment with neuromuscular junction blocking agents. *Crit Care Med*. 1991;100:1125-30.
- Steinberg KP, Hudson LD, Goodman RB, et al. Efficacy and safety of corticosteroids for persistent acute respiratory distress syndrome. *N Engl J Med*. 2006;354:1671-84.
- Partridge B, Ahrams J, Bazemore C, Rubin R. Prolonged neuromuscular blockade after long term infusion of vecuronium bromide in the intensive care unit. *Crit Care Med*. 1990;18:1177-9.
- Kupfer Y, Okrent D, Twersky R, Tessler S. Disuse atrophy in a ventilated patient with status asthmaticus receiving neuromuscular blockade. *Crit Care Med*. 1987;15:795
- Kaplan PW, Rocha W, Sanders DB, D'Souza B, Spock A. Acute steroid tetraplegia following status asthmaticus. *Pediatrics*. 1986;78:121-3.
- Segredo V, Caldwell JE, Matthay MA, Sharma ML, Gruenke LD, Miller RD. Persistent paralysis in critically ill patients after long-term administration of vecuronium. *N Engl J Med*. 1992;327:524-8.
- Testelmans D, Maes K, Wouters P, et al. Rocuronium exacerbates mechanical ventilation-induced diaphragm dysfunction in rats. *Crit Care Med*. 2006;34:3018-23.
- Stewart TE, Meade MO, Cook DJ, et al. Evaluation of a ventilation strategy to prevent barotrauma in patients at high risk for acute respiratory distress syndrome. Pressure- and Volume-Limited Ventilation Strategy Group. *N Engl J Med*. 1998;338:355-61.