

CASE REPORT

Bartter-like syndrome in an adult female receiving prolonged therapy with systemic colistin

Y. Özdemir¹, N. Kooijman², J. van Os², A. Braber³

The first two authors contributed equally to this work

¹Emergency Department, ²Department of Internal Medicine, and ³Intensive Care, Gelre Hospital, Zutphen, the Netherlands

Correspondence

Y. Ozdemir - 7.yildiz@gmail.com

Keywords - colistin, Bartter-like syndrome, electrolyte deficiency

Abstract

We present a case of a 36-year-old woman who developed severe electrolyte deficiencies following treatment with intravenous colistin for three months due to hip prosthesis infection with a multidrug resistant *Pseudomonas aeruginosa*. The metabolic abnormalities, which resembled those of Bartter syndrome, reversed after the colistin treatment was discontinued. A Bartter-like syndrome has been described following use of antibiotics such as aminoglycosides. However, few cases of an acquired form of Bartter-like syndrome are documented following use of colistin.

Introduction

Bartter syndrome is a congenital autosomal recessive renal disorder characterised by a defect in the thick ascending limb of the loop of Henle which causes renal salt wasting, hypokalaemia and metabolic alkalosis. An acquired form, Bartter-like syndrome, is associated with the use of a variety of antibiotics.^[1-6] Of these, only five cases have been reported in which Bartter-like syndrome was associated with systemic colistin use.^[1,3,6-8] Colistin is an old antibiotic, which was previously abandoned in clinical practice due to nephrotoxicity and neurotoxicity.^[9,10] However, the rise of multidrug resistant gram-negative bacteria has resulted in renewed interest in colistin.^[11]

Among these multidrug resistant bacteria, carbapenem-resistant *Pseudomonas aeruginosa* has been classified as 'Priority 1: critical' by the World Health Organisation for research and development of new antibiotics.^[12] We present a case of a patient with metabolic alterations resembling Bartter-like syndrome following treatment with intravenous colistin for three months due to a prosthetic joint infection with carbapenem-resistant *Pseudomonas aeruginosa*.

Case report

A 36-year-old woman was brought to the emergency department with severe muscle paresis. She had undergone a right hip

arthroplasty in Belarus in 2015 after a septic arthritis with *Staphylococcus aureus*. She moved to the Netherlands, where a prosthetic infection was diagnosed. The prosthesis was removed followed by a girdlestone procedure in another hospital in May 2018. Perioperative cultures of the osteosynthetic material and synovial fluid revealed a multidrug resistant *Pseudomonas aeruginosa*. According to the antibiogram, she was treated at home, with specialised nursing care, with ceftazidime 6 grams/day and colistin 4.5 million IU twice-daily for the following three months via a peripherally inserted central catheter. At the time of presentation, the full three months of treatment had been completed and all medication discontinued for two days. Her most apparent symptoms were extreme weakness and difficulty in breathing. She complained of difficulty urinating in the last month after experiencing increased urination in the first two months. Also, one month before presentation, she experienced some constipation. She had used laxatives up to three times a week without any effect. She had a decreased appetite and vomiting starting early in her colistin treatment. The vomiting ceased after a couple of weeks and she had a specific craving for salty foods. In the third month she again experienced nausea and loss of appetite. There was no diarrhoea. She was otherwise healthy and did not use any other medication, alcohol or recreational drugs. She had no history or other symptoms of acute kidney injury. Her renal function was normal at presentation. Upon examination, fasciculations were visible throughout her body. Trousseau's sign was visible in both hands without a specific trigger. Chvostek's sign was tested but not visible. Her vital signs were unremarkable. Lab results showed severe depression of the serum electrolytes and metabolic alkalosis with normal renal function (table 1). The electrocardiogram showed flattened and inverted T waves (figure 1). Analysis of a urine sample in the emergency department and a 24-hour urine analysis, taken shortly after starting supplementation (table 1),

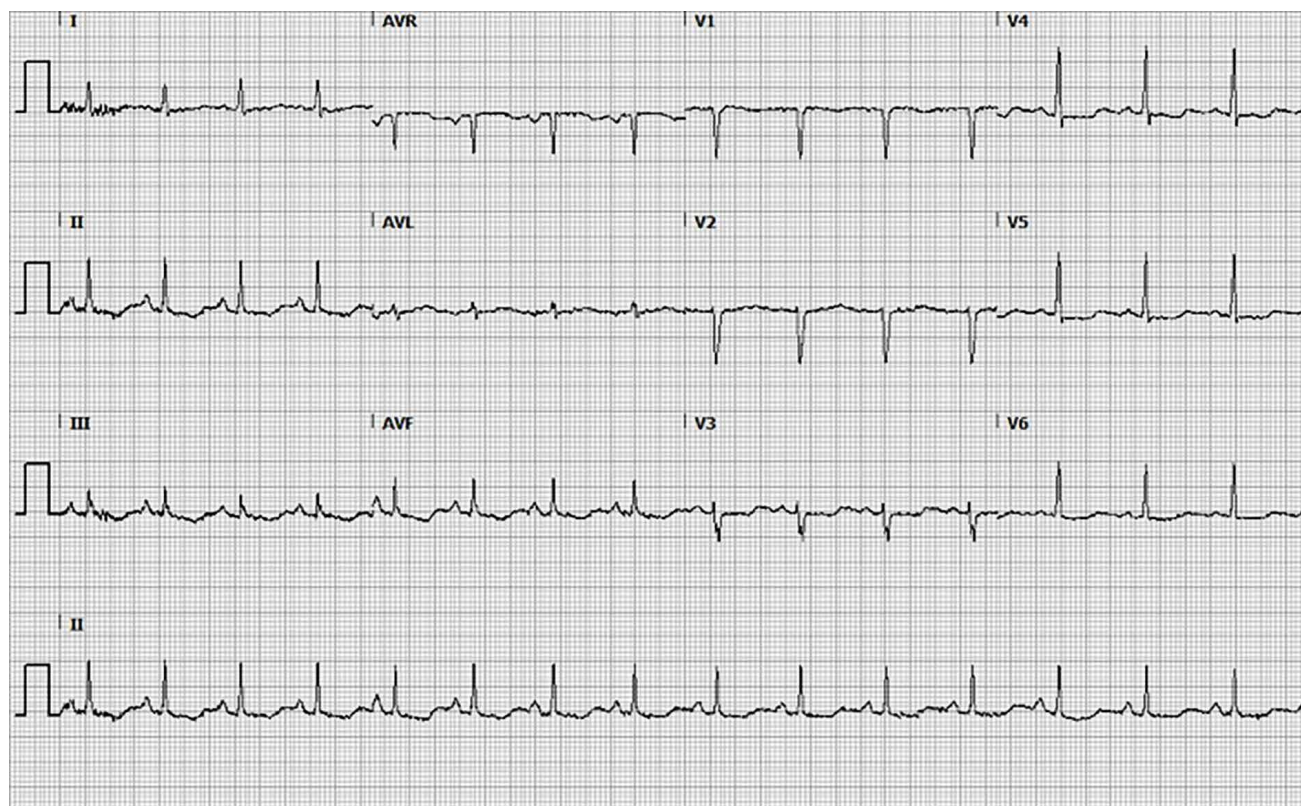


Figure 1. ECG in the emergency department

showed increased secretion of all electrolytes indicating renal loss. She was admitted to our high care unit for five days, where she received high-dose supplementation of electrolytes: up to 50 grams of magnesium IV, 34 grams of calcium IV, 900 mmol of potassium IV and 400 mmol orally. She was transferred to the internal medicine unit and electrolyte suppletion continued

Table 1. Electrolyte measurements

Blood measurements in the ED	Reference range	
Creatinine ($\mu\text{mol/l}$)	86	50-100
GFR	75	>60
Sodium (mmol/l)	135	135-145
Potassium (mmol/l)	1.9	3.5-5.0
Calcium (mmol/l)	1.57	2.10-2.55
Albumin (g/l)	36	35-50
Magnesium (mmol/l)	<0.25	0.60-1.1
Phosphate (mmol/l)	0.61	0.70-1.50
24-hour urine analysis (690 ml)		
Creatinine (mmol/24h)	11.1	10-42
Sodium (mmol/24h)	531	130-200
Potassium (mmol/24h)	218	25-125
Calcium (mmol/24h)	14.4	<8
Magnesium (mmol/24h)	15.50	3.0-5.0

GFR = glomerular filtration rate

orally. Hyperaldosteronism was deemed unlikely as she was normotensive with systolic pressures ranging from 105-120 mmHg. Aldosterone and renin were therefore not measured upon admission. Treatment with spironolactone and diclofenac was started in an attempt to limit renal loss of electrolytes. During admission, her renal function remained within the normal range. Gradually, the concentration of the serum electrolytes improved. All the electrolytes except magnesium normalised fully and all suppletion except magnesium was stopped one month after discontinuation of the antibiotic treatment. Our patient recovered completely and could be discharged. In the weeks following discharge, the serum levels of all the electrolytes remained stable. Serum levels of magnesium remained stable at a low-normal level after several weeks of oral suppletion after hospital discharge. Several months after the event, in another hospital, there was a re-challenge with systemic colistin because she was re-operated on her hip. In this period the hypomagnesaemia remained. She was supplemented for several weeks and now magnesium has completely stopped.

Discussion

We present a patient who developed severe electrolyte deficiencies and metabolic alkalosis due to renal loss after prolonged systemic therapy with colistin. The metabolic disturbances observed resembled those seen in Bartter's syndrome, a group of congenital autosomal recessive disorders

affecting the distal segment of the nephron. It is characterised by, among other things, electrolyte deficiencies caused by renal wasting, metabolic alkalosis and hormonal abnormalities, such as hyperreninaemia and hyperaldosteronism without hypertension.^[13]

Several mutations in different ion transporters have been associated with the pathogenesis of Bartter's syndrome. Congenital Bartter's syndrome types 1-4 are due to loss-of-function mutations in the sodium-potassium-chloride cotransporter, ATP-regulated potassium channel, kidney-specific basolateral chloride channel and beta-subunit of basolateral chloride channel, respectively.^[14] Bartter's syndrome type 5 is caused by gain-of-function mutations in the calcium-sensing receptor (CaSR) in the thick ascending loop of Henle and distal convoluted tubule, leading to loss of sodium, potassium, chloride, calcium and magnesium.^[14] Activation of the CaSR is also believed to be involved in the pathogenesis of some acquired forms of Bartter's syndrome,^[15] for example in aminoglycosides.^[2] Other drugs associated with acquired forms of Bartter's syndrome include amphotericin B, cisplatin and tuberculostatic agents (capreomycin and viomycin).^[14]

Colistin is a bactericidal polymyxin antibiotic, composed of the polymyxins E1 and E2, acting against gram-negative bacilli.^[16] It is unclear how colistin can cause this type of tubular dysfunction. Literature has mainly described nephrotoxicity following use of colistin as loss of renal function and renal failure.^[9,10,17] To date, tubular dysfunction associated with the use of colistin is not well described. We hypothesise that, like aminoglycosides, colistin may act in a way mimicking the mutations seen in Bartter's syndrome, which would resemble activation of the CaSR as in Bartter's syndrome type 5.

Even though our patient reported nausea, vomiting and use of laxatives, this accounted insufficiently for the severity and prolonged duration of the metabolic alterations seen. In addition, there were evident signs of a renal origin of the electrolyte disturbances present in urine analysis. There was no sign of contributing gastrointestinal loss of electrolytes during admission. Our patient was simultaneously treated with colistin and ceftazidime. Despite its widespread use, no reports of electrolyte disturbances after use of ceftazidime are described in literature. In contrast, there are several reports of hypokalaemia, hypomagnesaemia, hypocalcaemia and Bartter-like syndrome following intravenous colistin administration.^[1,3,6-8] Furthermore, the recurrent electrolyte deficiencies in another hospital, after she received colistin for the second time, strengthens our hypothesis.

We calculated a score of 7 on the Naranjo causality scale for adverse drug effects.^[8] This scale ranges from -4 to 13. This score corresponds with Bartter-like syndrome being a probable adverse drug effect due to antibiotic treatment. We also reported this side effect to the Netherlands Pharmacovigilance Centre Lareb.

Conclusion

In conclusion, this case report suggests a causal link between prolonged intravenous colistin use and metabolic disturbances resembling Bartter-like syndrome. The emergence of multidrug resistant micro-organisms, such as gram-negative bacteria including *Pseudomonas aeruginosa*, has led to renewed interest in systemic use of colistin.^[18,19] Therefore, further observational research into the prevalence and mechanisms of these side effects is necessary. It may be recommended to regularly check levels of electrolytes during therapy with systemic colistin.

Disclosures

All authors declare no conflict of interest. No funding or financial support was received.

Written informed consent was obtained from the patient for the publication of this case report.

References

1. Cakir U, Alan S, Zeybek C, et al. Acquired bartter-like syndrome associated with colistin use in a preterm infant. *Ren Fail.* 2013;35:411-3.
2. Chou CL, Chen YH, Chau T, et al. Acquired bartter-like syndrome associated with gentamicin administration. *Am J Med Sci.* 2005;329:144-9.
3. Kamal Eldin T, Tosone G, Capuano A, et al. Reversible Hypokalemia and Bartter-Like Syndrome during Prolonged Systemic Therapy with Colistimethate Sodium in an Adult Patient. *Drug Saf Case Rep.* 2017;4:10.
4. Sandal G, Akbay S, Ozen M. Acquired Bartter-like syndrome association with netilmicin therapy in an extremely low birth weight infant. *Ren Fail.* 2014;36:123-5.
5. Singh J, Patel ML, Gupta KK, et al. Acquired Bartter syndrome following gentamicin therapy. *Indian J Nephrol.* 2016;26:461-3.
6. Alan S, Yildiz D, Erdev O, et al. Efficacy and safety of intravenous colistin in preterm infants with nosocomial sepsis caused by *Acinetobacter baumannii*. *Am J Perinatol.* 2014;31:1079-86.
7. Choksi TS, Syed. Prolonged Intravenous Colistin Use Associated with Acquired Bartter-Like Syndrome in an Adult Patient. *Eur Med J.* 2018;102-5.
8. Ipek MS, Aktar F, Okur N, et al. Colistin use in critically ill neonates: A case-control study. *Pediatr Neonatol.* 2017;58:490-6.
9. Forrest A, Garonzik SM, Thamlikitkul V, et al. Pharmacokinetic/Toxicodynamic Analysis of Colistin-Associated Acute Kidney Injury in Critically Ill Patients. *Antimicrob Agents Chemother.* 2017;61(11).
10. Ordooei Javan A, Shokouhi S, Sahraei Z. A review on colistin nephrotoxicity. *Eur J Clin Pharmacol.* 2015;71:801-10.
11. van Dijk K, Wagemakers A, Vandenbroucke-Grauls CMJEV. Behandeling van infecties met zeer resistente bacteriën. *Ned Tijdschrift Geneeskunde.* 2018;126:D2834.
12. Tacconelli E, Carrara E, Savoldi A, et al. Discovery, research, and development of new antibiotics: the WHO priority list of antibiotic-resistant bacteria and tuberculosis. *Lancet Infect Dis.* 2018;18:318-27.
13. Kleita R, Bockenhauer D. Bartter syndromes and other salt-losing tubulopathies. *Nephron Physiol.* 2006;104:73-80.
14. Yu TM, Lin SH, Ya-Wen C, et al. A syndrome resembling Bartter's syndrome in sarcoidosis. *Nephrol Dial Transplant.* 2009;24:667-9.
15. Watanabe S, Fukumoto S, Chang H, et al. Association between activating mutations of calcium-sensing receptor and Bartter's syndrome. *Lancet.* 2002;360:692-4.
16. Tran TB, Velkov T, Nation RL, et al. Pharmacokinetics/pharmacodynamics of colistin and polymyxin B: are we there yet? *Int J Antimicrob Agents.* 2016;48:592-7.
17. Spapen H, Jacobs R, Van Gorp V, et al. Renal and neurological side effects of colistin in critically ill patients. *Ann Intensive Care.* 2011;1:14.
18. Falagas ME, Kasiakou SK. Toxicity of polymyxins: a systematic review of the evidence from old and recent studies. *Crit Care.* 2006;10:R27.
19. Michalopoulos AS, Tsiodras S, Rellos K, et al. Colistin treatment in patients with ICU-acquired infections caused by multiresistant Gram-negative bacteria: the renaissance of an old antibiotic. *Clin Microbiol Infect.* 2005;11:115-21.