

PHOTO QUIZ

The brain has returned at ease, not suspecting another disaster

W.M. van den Bergh

Department of Critical Care, University Medical Center Groningen, University of Groningen, Groningen, the Netherlands

Correspondence

W.M. van den Bergh - w.m.van.den.bergh@umcg.nl

A 43-year-old woman with a history of smoking and moderate alcohol consumption was admitted to the emergency room for a transient period of unconsciousness of 5-10 minutes while sitting on the couch, which was witnessed by her husband. A CT brain revealed a subarachnoid haemorrhage based on a ruptured aneurysm of the right-sided posterior communicating artery. On admission to the ICU she was fully conscious without neurological deficit. The aneurysm was treated by means of endovascular coiling which was an uncomplicated procedure. She was discharged to the ward the following day.

Five days after the bleeding she developed a hemiparesis of the left arm and face. A CT brain showed hypodensities that were not present on the admission CT shortly after the bleeding (*figure 1*).

What is your diagnosis?

ANSWER

You will find the answer on page 249 of this issue.

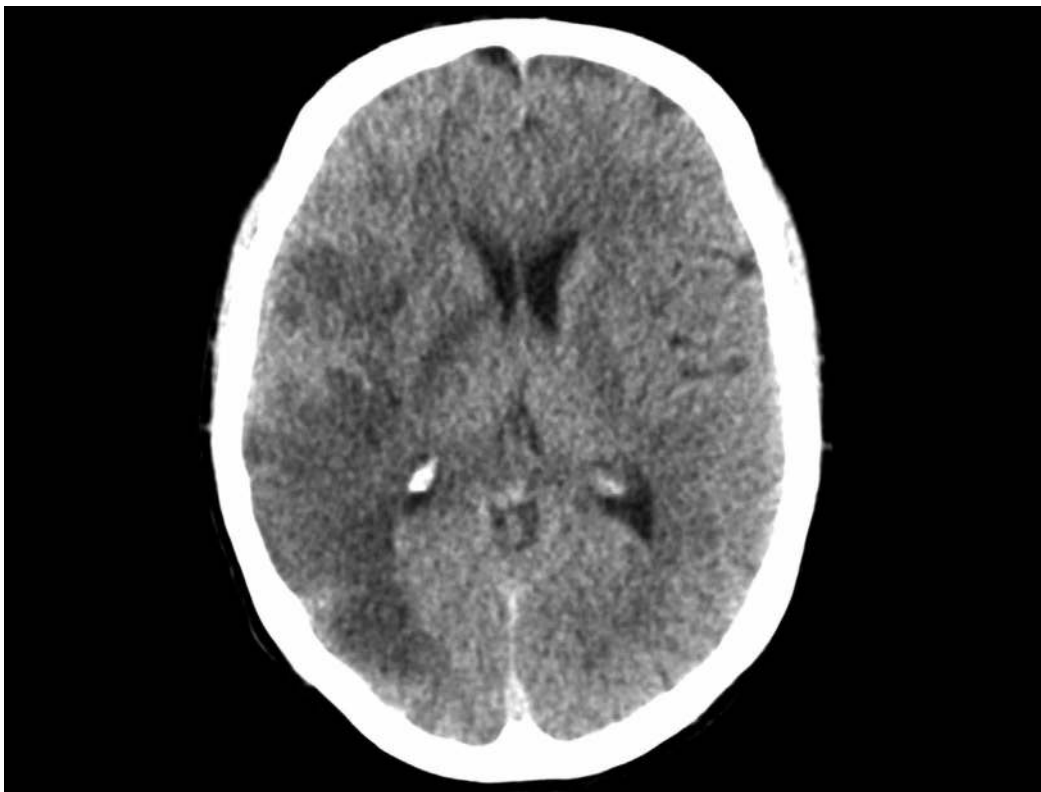


Figure 1. Brain CT 5 days after subarachnoid haemorrhage